



Sinonasal and Asthma Outcomes after Aspirin Desensitization following Endoscopic Sinus Surgery in Aspirin Exacerbated Respiratory Disease

Keun-Ik Yi¹, Sung-Dong Kim², Yong-Wan Kim¹, Kyu-Sup Cho²

¹Department of Otorhinolaryngology-Head & Neck Surgery, Inje University Haeundae Paik Hospital, Busan, Korea

²Department of Otorhinolaryngology and Biomedical Research Institute, Pusan National University School of Medicine, Pusan National University Hospital, Busan, Korea

ABSTRACT

Aspirin exacerbated respiratory disease (AERD) is a well-known disease characterized by the triad of bronchial asthma, nasal polyps, and aspirin intolerance. AERD has been known to be the most severe form of chronic rhinosinusitis, marked by a larger polyp burden and higher rates of recurrence after endoscopic sinus surgery (ESS). Although ESS improves sinonasal symptoms and asthma severity score, it does not address the underlying abnormal metabolism of arachidonic acid. Herein, we describe two cases of AERD presented as recurrent nasal polyposis after ESS, which was successfully treated with aspirin desensitization following ESS.

KEY WORDS: Asthma, Aspirin-induced; Desensitization, Immunologic; Nasal polyps; Sinusitis; Endoscopic sinus surgery.

Introduction

Chronic rhinosinusitis is a heterogeneous disease and, beyond the division of with or without nasal polyps, a variety of phenotypes have been identified. Aspirin-exacerbated respiratory disease (AERD) represents a particularly recalcitrant variant of chronic rhinosinusitis with nasal polyps accompanied by asthma and aspirin intolerance.¹⁾ Due to the large burden of nasal polyps, endoscopic sinus surgery (ESS) is usually performed to improve symptoms and to promote steroid delivery.²⁾ However, AERD is notorious for being recalcitrant and patients often need revision surgery. Therefore, it is ideal for patients with AERD to receive additional medical treatment following ESS to prevent recurrence of chronic rhinosinusitis with nasal polyps.³⁾ We report two

cases of improved outcomes of sinonasal status and asthma control after aspirin desensitization following ESS in AERD.

Case Reports

Case 1

A 27-year-old male was referred to otorhinolaryngology department because of nasal obstruction and anosmia from internal medicine. He had undergone prior ESS 6 years and 2 years ago. The patient's medical history was otherwise unremarkable. The bronchial challenges with L-lysine aspirin showed a 25% decrease in the forced expiratory volume in one second (FEV1) at 300 mg/mL, which is acceptable to diagnosis with AERD. Revision ESS was performed under

Received: December 3, 2021 / Revised: December 24, 2021 / Accepted: January 20, 2022

Corresponding author: Kyu-Sup Cho, Department of Otorhinolaryngology and Biomedical Research Institute, Pusan National University School of Medicine, Pusan National University Hospital, Busan 49241, Korea

Tel: +82-51-240-7824, Fax: +82-51-246-8668, E-mail: choks@pusan.ac.kr

Copyright © 2022. The Busan, Ulsan, Gyeongnam Branch of Korean Society of Otolaryngology-Head and Neck Surgery.

This is an Open Access article distributed under the terms of the Creative Commons Attribution Non-Commercial License (<http://creativecommons.org/licenses/by-nc/4.0/>) which permits unrestricted non-commercial use, distribution, and reproduction in any medium, provided the original work is properly cited.

general anesthesia. Four weeks following ESS, oral aspirin challenge and desensitization were performed. Patients began with a 25 mg oral aspirin, followed by escalating doses of aspirin progressing through 50 mg, 100 mg, 150 mg, and 300 mg, administered at 90 minutes intervals under intensive monitoring. The maintenance dose is 500 mg twice daily for one month, followed by 500 mg daily. Nasal symptom scores assessed by the Sinonasal Outcomes Test-22 (SNOT-22) and Rhino-Sinusitis Disability Index (RSDI) were improved at 4 weeks post-surgery and further decreased at 2 years post-desensitization (Fig. 1A, B). Furthermore, preoperative endoscopic polyp scores and Lund-Kennedy (LK) endoscopic scores were decreased and sustained post-desensitization throughout the follow-up period (Fig. 1C, D). Level of asthma symptom control was improved from partly controlled status preoperatively to well controlled status at 4 weeks post-surgery and 2 years post-desensitization accord-

ing to the Global Initiative for Asthma (GINA) guideline: 1=uncontrolled, 2=partly controlled, 3=well controlled (Fig. 2A). FEV₁ increased from 91% to 104% at 2 years post-desensitization (Fig. 2B). The degree of asthma control by questionnaire using Asthma Control Test (ACT) and quality of life questionnaire for adult Korean asthmatics (QLQAKA) was improved post-surgery and remained at 2 years post-desensitization (Fig. 2C, D).

Case 2

A 41-year-old woman with AERD presented posterior nasal drip and olfactory dysfunction two years ago. She had undergone nasal polypectomy due to nasal congestion and anosmia at a local clinic several times. Revision ESS was performed, which is followed by oral aspirin desensitization at 4 weeks post-surgery. Final maintenance doses of aspirin were 500 mg once a day. The SNOT-22 and RSDI scores

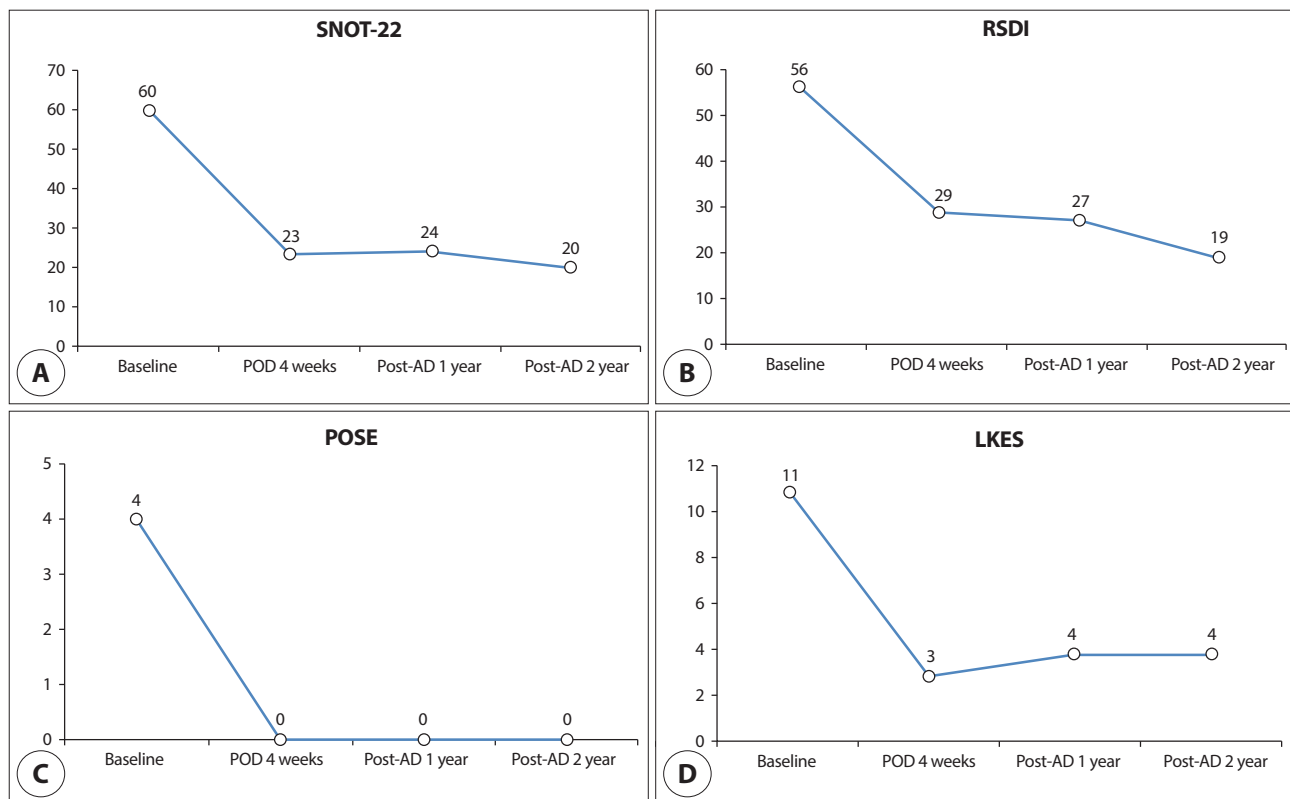


Fig. 1. Nasal symptom scores and endoscopic assessment of case 1. The SNOT-22 (A) and RSDI (B) scores were improved at 4 weeks post-surgery and further decreased at 2 years post-desensitization. Preoperative endoscopic polyp scores (C) and Lund-Kennedy endoscopic scores (D) were decreased and sustained post-desensitization throughout the follow-up period. AD: aspirin desensitization, LKES: Lund-Kennedy endoscopic scores, POD: postoperative day, POSE: peri-operative sinus endoscopy, RSDI: rhino-sinusitis disability index, SNOT-22: Sinonasal outcomes test-22.

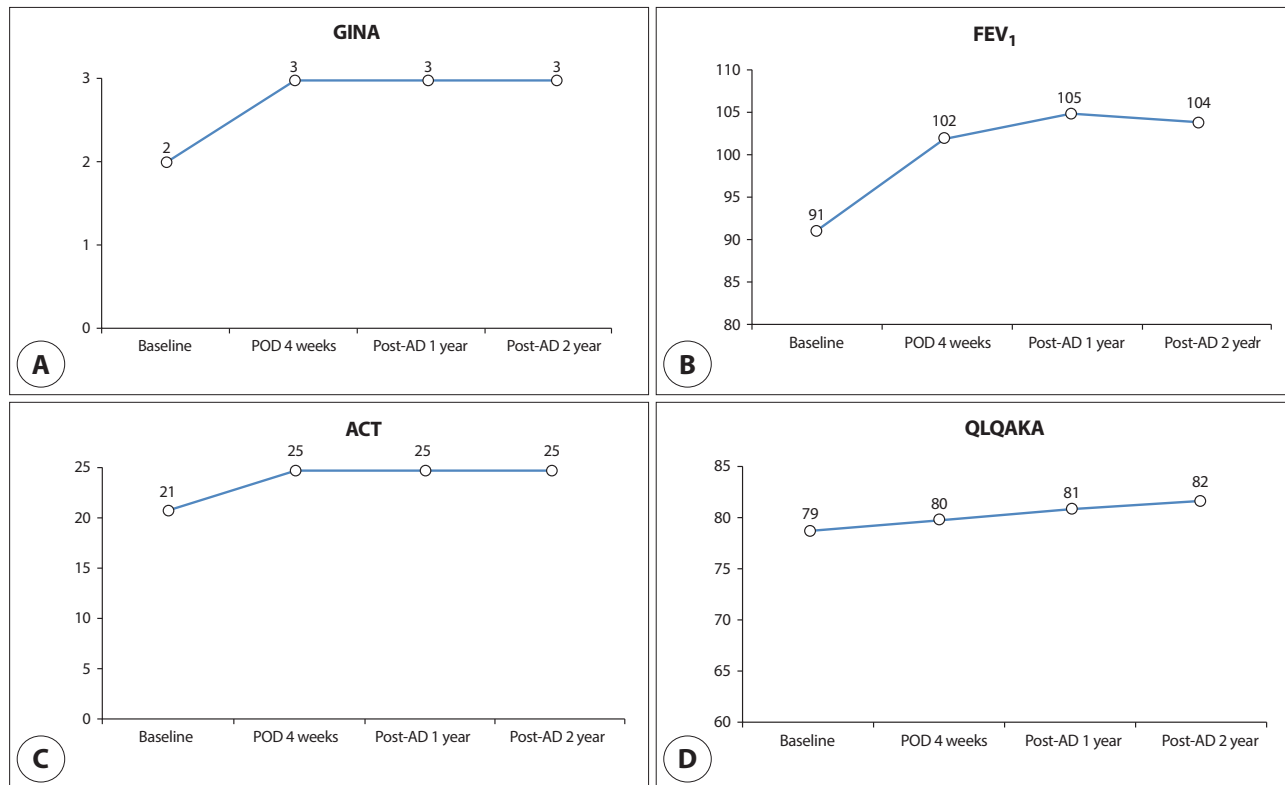


Fig. 2. Asthma control status of case 1. Level of asthma symptom control (A) was improved from partly controlled status preoperatively to well controlled status after 4 weeks post-surgery and 2 years post-desensitization according to the GINA guideline. FEV₁ (B), ACT (C), and QLQAKA (D) scores were improved at 4 weeks post-surgery and remained at 2 years post-desensitization. AD: aspirin desensitization, ACT: asthma control test, FEV₁: forced expiratory volume in one second, POD: postoperative day, QLQAKA: quality of life questionnaire for adult Korean asthmatics, GINA: global initiative for asthma.

decreased after surgery and further decreased at 2 years post-desensitization (Fig. 3A, B). Postoperative endoscopic polyp scores and LK scores decreased and continued to remain low at all time points throughout the follow-up period (Fig. 3C, D). Level of asthma symptom control based on the GINA guideline was improved to well controlled state at after 4 weeks post-surgery and 2 years post-desensitization (Fig. 4A). FEV₁ and ACT scores remained increased at all time points throughout the follow-up period (Fig. 4B, C). The QLQAKA scores were improved at 4 weeks post-surgery and further increased at 2 years post-desensitization (Fig. 4D).

Discussion

AERD was first described in 1922 by Widal et al. as a triad of symptoms: asthma, nasal polyps, and aspirin intolerance.⁴ Although the exact mechanism remains unclear,

AERD is thought to be a non-allergic hypersensitivity reaction associated with an abnormal metabolism of arachidonic acid.⁵ Many patients with AERD first visited the otorhinolaryngology department because nasal obstruction and anosmia are the most common symptoms of AERD. Furthermore, these patients usually have intractable chronic rhinosinusitis that requires multiple surgeries. The present cases describe the successful outcomes of sinonasal status and asthma control after post-ESS aspirin desensitization using an endoscopic scoring system and validated symptom questionnaires in AERD patients.

Aspirin sensitivity was determined by a patient's history of dyspnea or asthma attacks after ingestion of aspirin or other nonsteroidal anti-inflammatory drug.⁶ However, the diagnosis of AERD could be confirmed only through the provocative aspirin challenge test by increasing doses of aspirin.^{7,8} Although oral challenges are the most commonly used and regarded as gold standard methods,⁸ bronchial

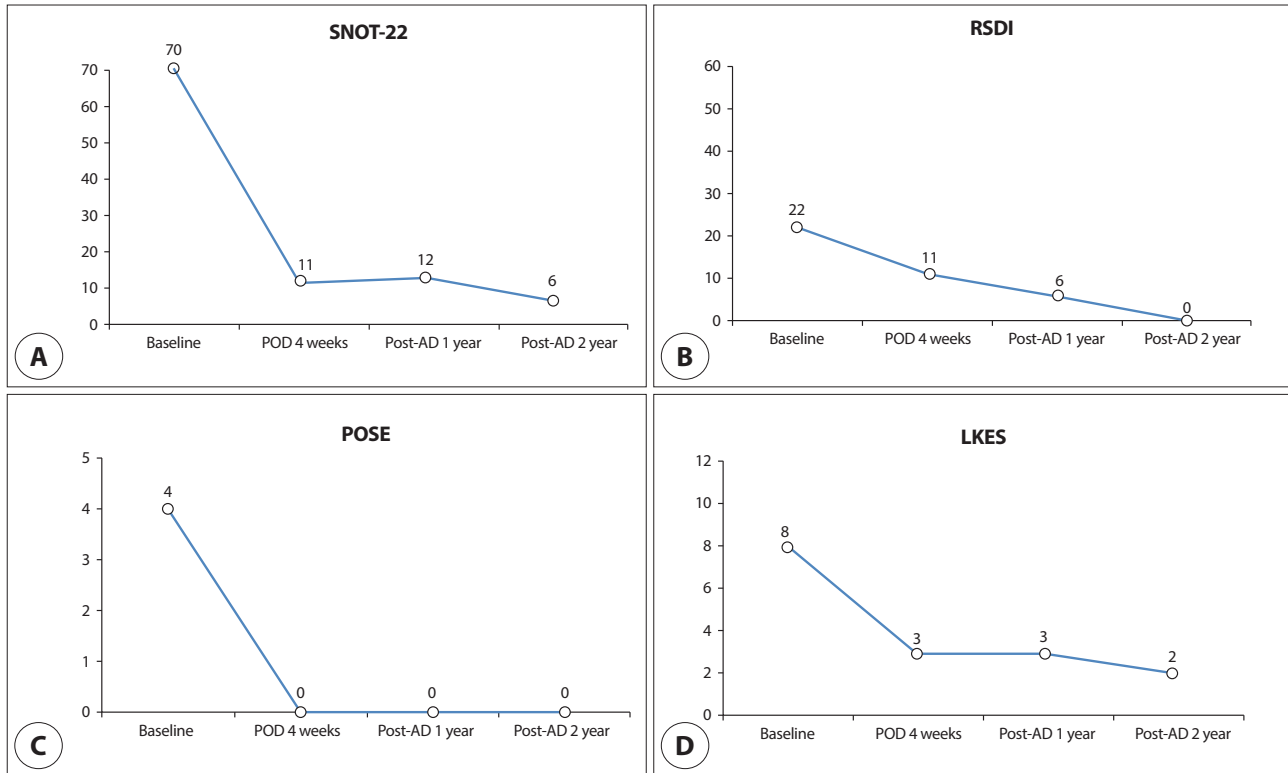


Fig. 3. Nasal symptom scores and endoscopic assessment of case 3. The SNOT-22 (A) and RSDI (B) scores decreased after surgery and further decreased at 2 years post-desensitization. Postoperative endoscopic polyp scores (C) and Lund-Kennedy endoscopic scores (D) decreased and continued to remain low at all time points throughout the follow-up period. AD: aspirin desensitization, LKES: Lund-Kennedy endoscopic scores, POD: postoperative day, POSE: peri-operative sinus endoscopy, RSDI: rhino-sinusitis disability index, SNOT-22: sinonasal outcomes test-22.

challenges with L-lysine aspirin were used in this study because this provocation is safer and faster to perform than oral route.

AERD may be medically treated according to established guidelines for managing asthma and chronic rhinosinusitis. Management usually proceeds through the use of topical corticosteroids and leukotriene-modifier drugs. In addition, steroid irrigation, oral steroids, immunotherapy, and anti-immunoglobulin E treatment might be considered as adjuvant medical treatment in patients with AERD. Aspirin desensitization has been recognized as a useful adjunct to ESS in the treatment of AERD patients, but is currently poorly used treatment.⁹⁾ Aspirin desensitization should be considered as a therapeutic option in patients requiring daily or frequent use of systemic corticosteroids to control asthma or rhinosinusitis symptoms, patients with aggressive nasal polyp formation requiring multiple ESS, and patients with other diseases or indications requiring use of aspirin or other

COX-1 inhibitors.

Although ESS clears the burden of gross nasal polyps and improves severity of asthma, it does not address the underlying abnormal metabolism of arachidonic acid. It is ideal that patients with refractory chronic rhinosinusitis with nasal polyps should be treated by aspirin desensitization after ESS because aspirin desensitization is most effective in preventing or retarding the regrowth of nasal polyps in the paranasal sinuses that have been surgically cleared. Although the optimal dose of aspirin for maintenance therapy has not been known, it should be at least 325 mg once a day and ideally twice a day.¹⁰⁾ To date, there has been no consensus on the initiation time and duration of aspirin desensitization therapy. In general, the starting point of aspirin desensitization was recommended 2-12 weeks after ESS,¹¹⁾ and it was actually performed between 3 and 6 weeks in several papers.^{9,12,13)} The duration of dosing was reported differently for each study, which was generally consistent with the

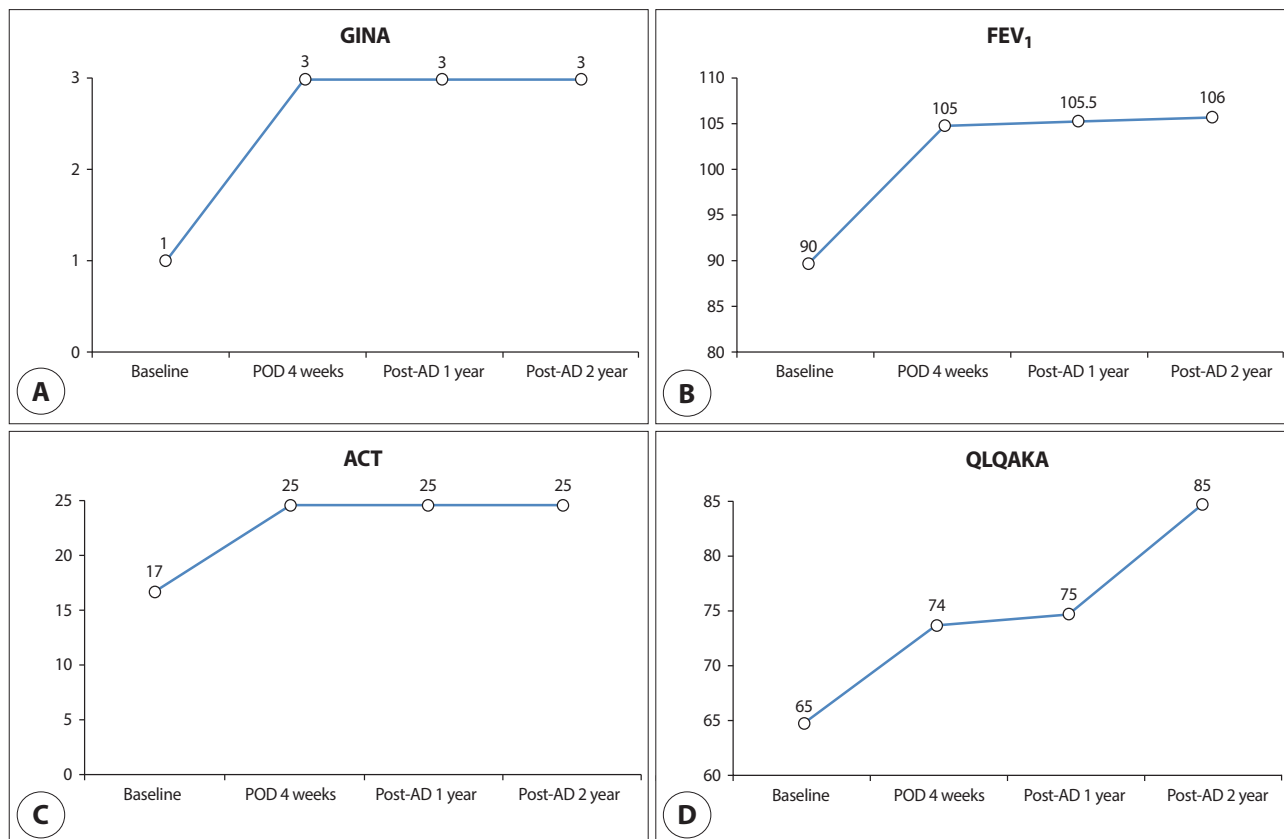


Fig. 4. Asthma control status of case 2. Level of asthma symptom control (A) based on the GINA guideline was improved to well controlled state at after 4 weeks post-surgery and 2 years post-desensitization. The improvement of FEV₁ (B) and ACT (C) scores were maintained throughout the follow-up period after desensitization. The QLQAKA scores (D) were improved at 4 weeks post-surgery and further increased at 2 years post-desensitization. AD: aspirin desensitization, ACT: asthma control test, FEV₁: forced expiratory volume in one second, POD: postoperative day, QLQAKA: quality of life questionnaire for adult Korean asthmatics.

duration of follow up. In this study, aspirin desensitization by daily oral intake of aspirin was performed at a month post-surgery. The maintenance dose of aspirin was 500 mg twice a day for one month, followed by 500 mg daily.

Aspirin desensitization therapy should be administered with caution due to the possibility of acute reaction including anaphylaxis. In addition, chronic use of it has been associated with upper GI bleeding and indigestion, increasing the risk, especially in elderly patients taking corticosteroids.¹¹⁾ Recently, biologics have been proposed as an alternative treatment for refractory chronic rhinosinusitis with nasal polyps. However, the cost-effectiveness of it in the setting of AERD has been questioned. On the other hand, aspirin desensitization after ESS was shown to be a favorable strategy in terms of cost-utility analysis, requiring minimal incremental cost to avoid additional revision

surgery due to persistent symptoms.¹⁴⁾ Aspirin desensitization following ESS showed a sustained preservation of the postsurgical improvements for the duration of the follow-up period. Aspirin desensitization well controlled sinonasal and asthma symptom scores, reduced the degree of nasal polyps formation, and improved FEV₁ scores and quality of life in patients with AERD at 24 months post-desensitization.

Conclusion

The AERD phenotype is known to be the most severe form of chronic rhinosinusitis showing higher rates of recurrence after ESS. Aspirin desensitization following ESS may reduce the recurrence rate of nasal polyps and help to maintain an improved sinonasal status and control asthmatic symptoms in patients with AERD.

Acknowledgements

Not applicable.

Funding Information

This study was supported by Biomedical Research Institute Grant (2013-E2), Pusan National University Hospital.

Conflicts of Interest

No potential conflict of interest relevant to this article was reported.

ORCID

Keun-Ik Yi, <https://orcid.org/0000-0002-7924-5646>

Sung-Dong Kim, <https://orcid.org/0000-0002-8436-5722>

Yong-Wan Kim, <https://orcid.org/0000-0002-6010-312X>

Kyu-Sup Cho, <https://orcid.org/0000-0002-4381-6996>

Author Contribution

Conceptualization: Cho KS.

Data curation: Yi KI.

Formal analysis: Yi KI.

Methodology: Kim SD.

Validation: Kim YW.

Investigation: Kim SD.

Writing - original draft: Yi KI.

Writing - review & editing: Yi KI, Kim SD, Kim YW, Cho KS.

Ethics approval

Not applicable.

References

- White AA, Stevenson DD. Aspirin-exacerbated respiratory disease. *N Engl J Med* 2018;379:1060-70.
- Larivée N, Chin CJ. Aspirin desensitization therapy in aspirin-exacerbated respiratory disease: a systematic review. *Int Forum Allergy Rhinol* 2020;10(4):450-64.
- Kim SD, Cho KS. Samter's triad: state of the art. *Clin Exp Otorhinolaryngol* 2018;11(2):71-80.
- Widal F, Abrami P, Lermoyez J. First complete description of the aspirin idiosyncrasy-asthma-nasal polyposis syndrome (plus urticaria)--1922 (with a note on aspirin desensitization). *J Asthma: Official J Assoc Care Asthma* 1987;24(5):297-300.
- Szczeklik A, Sanak M, Nizankowska-Mogilnicka E, Kiełbasa B. Aspirin intolerance and the cyclooxygenase-leukotriene pathways. *Curr Opin Pulm Med* 2004;10(1):51-6.
- Szczeklik A, Nizankowska E. Clinical features and diagnosis of aspirin induced asthma. *Thorax* 2000;55 Suppl 2:S42-4.
- Bochenek G, Nizankowska E, Szczeklik A. Testing for aspirin hypersensitivity. *Allergy* 2002;57(7):562-5.
- Nizankowska E, Bestyńska-Krypel A, Cmiel A, Szczeklik A. Oral and bronchial provocation tests with aspirin for diagnosis of aspirin-induced asthma. *Eur Respir J* 2000;15(5):863-9.
- Havel M, Ertl L, Braunschweig F, Markmann S, Leunig A, Gamarra F, et al. Sinonasal outcome under aspirin desensitization following functional endoscopic sinus surgery in patients with aspirin triad. *Eur Arch Otorhinolaryngol* 2013;270(2):571-8.
- Lee RU, Stevenson DD. Aspirin-exacerbated respiratory disease: evaluation and management. *Allergy Asthma Immunol Res* 2011;3(1):3-10.
- Levy JM, Rudmik L, Peters AT, Wise SK, Rotenberg BW, Smith TL. Contemporary management of chronic rhinosinusitis with nasal polyposis in aspirin-exacerbated respiratory disease: an evidence-based review with recommendations. *Int Forum Allergy Rhinol* 2016;6(12):1273-83.
- Adappa ND, Ranasinghe VJ, Trope M, Brooks SG, Glicksman JT, Parasher AK, et al. Outcomes after complete endoscopic sinus surgery and aspirin desensitization in aspirin-exacerbated respiratory disease. *Int Forum Allergy Rhinol* 2018;8(1):49-53.
- Cho KS, Soudry E, Psaltis AJ, Nadeau KC, McGhee SA, Nayak JV, et al. Long-term sinonasal outcomes of aspirin desensitization in aspirin exacerbated respiratory disease. *Otolaryngol Head Neck Surg* 2014;151(4):575-81.

14. Yong M, Wu YQ, Howlett J, Ballreich J, Walgama E, Thamboo A. Cost-effectiveness analysis comparing dupilumab and aspirin desensitization therapy for chronic rhinosinusitis with nasal polyposis in aspirin-exacerbated respiratory disease. *Int Forum Allergy Rhinol* 2021;11(12):1626-36.