

Paranglioma of the External Auditory Canal : A Case Report

Hyo-Seok Seo, MD, Sung-Won Choi, MD, Soo-Keun Kong, MD, PhD and Eui-Kyung Goh, MD, PhD

Department of Otorhinolaryngology-Head & Neck Surgery, Pusan National University School of Medicine, Busan, Korea

– ABSTRACT –

Parangliomas are benign tumors originating from paraganglia and characterized by a collection of small neuroendocrine organs. In the ear, paragangliomas are commonly found in the middle ear or jugular bulb. Parangliomas of the external auditory canal (EAC) are extremely rare. Here, we present our experience with a 25-year-old woman who was admitted to our otology department for intermittent scanty left otorrhea. A physical examination revealed a 3 × 4 mm-sized pedunculated mass on upper portion of the anterior wall of the left EAC. Computed tomography revealed a non-specific, soft tissue mass in the left EAC without erosion of the underlying bony canal. An excisional biopsy was performed. Histopathological features favored a diagnosis of paraganglioma. At a 9 month post-operative follow-up, the patient had a patent external auditory canal without recurrence. Parangliomas tend to be locally destructive, and can lead to disability in the form of hearing loss especially in EAC. Although paraganglioma is a very rare disease, our results indicate that it should be included in the differential diagnosis of an EAC mass. (*J Clinical Otolaryngol* 2017;28:234–237)

KEY WORDS : Paranglioma · External ear canal · Diagnosis · Histopathology.

Introduction

Parangliomas are benign tumors originating from neuroectodermal tissues and characterized by a collection of small neuroendocrine organs.¹⁻³ Parangliomas are most common in the adrenal glands and are anatomically classified as cervical (carotid body tumors and glomus vagale) and temporal/jugulotympanic (glomus jugulare and glomus tympanicum) in the head and neck region.^{3,4}

Parangliomas rarely occur in the head and neck, but often found in the middle ear cavity. In the ear, para-

gangliomas are represented as glomus bodies, and glomus bodies are found in close association with the Jacobson's nerve (tympanic branch of the glossopharyngeal nerve), Arnold's nerve (auricular branch of the vagus nerve), or the adventitia of the jugular bulb.⁵ A confinement of a paraganglioma to the external auditory canal (EAC) is even more rare.¹⁻³ Only five cases of a paraganglioma confined to the EAC have been reported. We present a case of a 25-year-old woman who was diagnosed with a paraganglioma that was confined to the EAC, but without recurrence to date following surgical treatment.

Case Report

A 25-year-old woman visited to our otology department for otorrhea that lasted for 3 weeks. Upon examination, a 3 × 4 mm-sized pedunculated mass was found on the upper portion of the anterior wall of the EAC (Fig. 1A). A reddish, soft and non-tender mass

논문접수일 : 2017년 9월 26일

논문수정일 : 2017년 10월 25일

심사완료일 : 2017년 11월 22일

교신저자 : 고의경, 49241 부산광역시 서구 구덕로 179

부산대학교 의학전문대학원 이비인후과학교실

전화 : (051) 240-7336 · 전송 : (051) 246-8668

E-mail : gohek@pusan.ac.kr

was completely covered with skin. The mass partially occluded the EAC, but the tympanic membrane was well visible and intact. All other otologic examinations were normal, including tympanometry and a pure tone audiometry test.

Computed tomography (CT) of the temporal bones revealed 3 mm-sized soft tissue density mass in the left EAC. The tympanic membrane was normal and there was no bony erosion (Fig. 1B, C). An excisional biopsy was performed under local anesthesia. The tumor was located beneath the epidermis and was well separated from the surrounding tissue. There was no bone erosion, similar to the CT findings. The mass was completely removed using an endaural approach and brisk bleeding was encountered. Bleeding control was performed and the operation was completed. Upon postoperative histopathology, the tumor was under the epidermis with a size of 4×4 mm. The boundary of the tumor was clear and Zellballen was located between the various sized blood vessels. Tumor cells were uniform in size and shape, having a rounded cell body and a clearly visible cell membrane. The boundary with surrounding cells was also clear. The tumor cells formed sheets and nests within a prominent vascular network. Tumor nests were composed of round to oval nuclei and abundant eosinophilic cytoplasm. Mitosis and necrosis were not observed (Fig. 2A, B). Immunohistochemical analysis yielded positive results for S-100

(sustentacular cells) and synaptophysin and negative results for chromogranin and smooth muscle antigen (SMA) (Fig. 2C, D). These histopathological findings confirmed the tumor as a paraganglioma.

The patient was discharged on the day of the operation without any problem. At a 9 month post-operative follow-up, the patient was doing well and without complications or tumor recurrence.

Discussion

A paraganglioma is a neuroectodermal tumor of paraganglia origin and most commonly found in the adrenal gland but arising elsewhere.⁶⁾ This tumor is rarely found in the head and neck regions, but is often found in the middle ear cavity. A paraganglioma that is confined to EAC, as in the present case, is very rare. In the ear, paragangliomas are represented as glomus bodies and glomus bodies are found in close association with Jacobson's nerve (the tympanic branch of the glossopharyngeal nerve), Arnold's nerve (the auricular branch of the vagus nerve), or the adventitia of the jugular bulb.⁵⁾ A paraganglioma confined to the EAC are related to the Arnold's nerves, and the tumor in our case is also thought to originate from the Arnold's nerve.

Only five cases of a paraganglioma confined to the EAC have been reported. The cases were mainly female patients who ranged in age from 19 to 49 years.

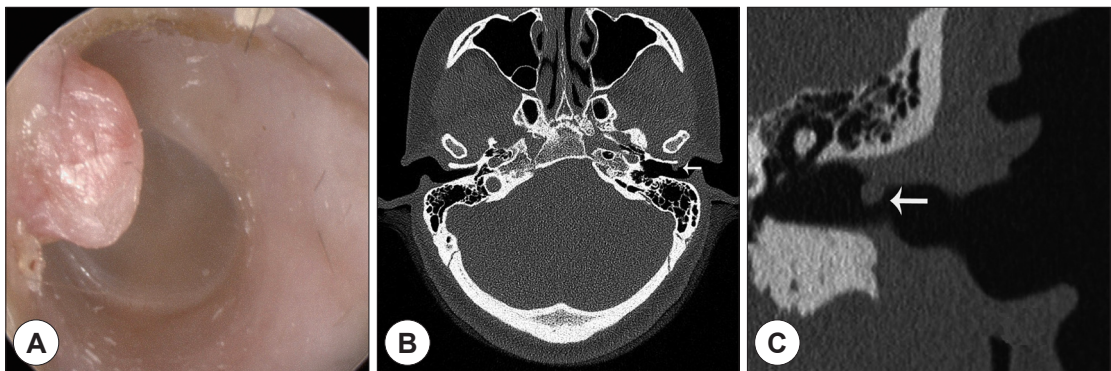


Fig. 1. A : Otoscopic findings show that the tumor is located on the anterior wall of the left external auditory canal. B : A computed tomography scan of temporal bones shows a mass (arrow) of a 3×4 mm-sized soft tissue density in the left external auditory canal (EAC). C : A coronal image shows a soft tissue density mass (arrow) in the left EAC, the tympanic membrane is normal, and no bony erosion is observed.

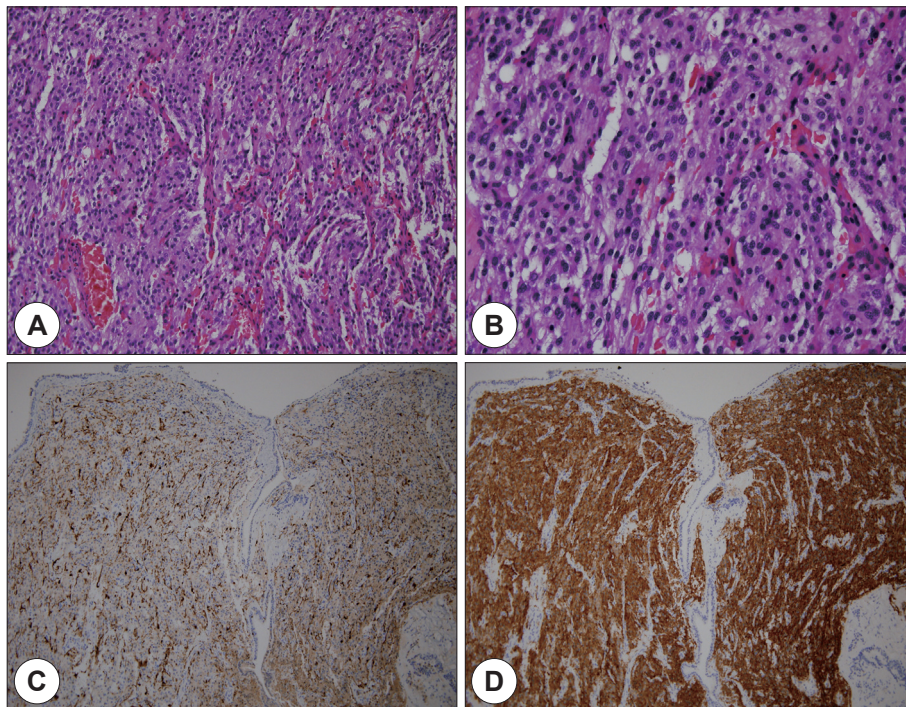


Fig. 2. Histopathologic findings of a paraganglioma showing a Zellballen pattern. (A) Shows hematoxylin & eosin (H & E) staining at $\times 200$ and (B) shows H & E staining at $\times 400$. Immunohistochemical findings show the tumor cells are negative for (C) S-100 ($\times 100$) but background sustentacular cells are positive. The tumor cells are positive (D) synaptophysin ($\times 100$).

The tumor location was not consistently observed along the anterior to superior wall. EAC tumors that are diagnosed as paragangliomas are usually firm and fixed tissue with an abundant blood flow. In most cases, the patients presented with a hearing disturbance because the involved EAC side was filled with the mass.^{1,2,7,8} However, in our case, a soft tumor was present in the upper portion of the anterior wall and there was no hearing disturbance. Age, sex, and symptoms are similar for patients with a paraganglioma, which usually occurs in the middle ear.^{9,10} The CT findings of these other EAC paraganglioma cases show no distinct difference from those of other tumors except that the tumor has soft tissue density and no bony involvement. Although CT and magnetic resonance imaging (MRI) are useful to diagnose paraganglioma of the middle ear,¹¹ they are not essential for such a diagnosis.^{1,2,7} The diagnosis of a paraganglioma requires a histopath-

ological examination and immunohistochemistry; Zellballen pattern is observed histopathologically, and immunohistochemical analysis is positive for neuron specific enolase, chromogranin, and s-100 (sustentacular cells).^{1,2,7,8} Surgical removal is the first-line treatment for paraganglioma in the head and neck,¹⁴ but conventional radiation therapy can be used if surgery is not possible.⁹ A paraganglioma that is confined to the EAC is rare, thus its recurrence should be evaluated through follow-up observation. Initially, we regarded the tumor in our case as a simple polyp. In general, the differential diagnosis of EAC polyps includes exostosis, osteoma, fibrous dysplasia, granuloma, ceruminous gland tumor, epidermoid, cholesteatoma, papilloma, and malignancies,^{12,13} but not paraganglioma.

Conclusion

A paraganglioma is a rare tumor with a slow growth rate, but this tumor can destroy bone tissue and lead to hearing loss, especially if it occurs in the EAC. A paraganglioma that is confined to the EAC has no typical symptoms that have been reported to date. Otoscopic findings and tumor locations are also variable. Thus, a paraganglioma in the EAC is not easily differentiated and diagnosed based on otoscopic findings and imaging tests, unlike those occurring in the middle ear. An EAC paraganglioma is rare, and thus may be misdiagnosed as a polyp, and the necessary diagnostic tests may not be performed. Our results suggest that a paraganglioma should be included in the differential diagnosis of an EAC tumor to avoid misdiagnosis and improper management.

This work was supported by clinical research grant from Pusan National University Hospital 2017.

REFERENCES

- 1) Singh KB, Hanna GS, Dinnen JS. *Paraganglioma of the external auditory canal. J Laryngol Otol* 1993;107(3):228-9.
- 2) Skinner LJ, Curran AJ, Barnes C, Timon CI. *Paraganglioma of the external auditory canal: an unusual case. J Laryngol Otol* 2000;114(5):370-2.
- 3) Hyams VJ, Batsakis JG, Michaels L. *Tumours of the Upper Respiratory Tract and Ear. Washington DC: Armed Forces Institute of Pathology;1988. p.306-10.*
- 4) Brown J. *Glomus jugulare tumours revisited: a 10 year statistical follow-up of 231 cases. Laryngoscope* 1985;95(3):284-8.
- 5) Guild SR. *The glomus jugulare: A non-chromaffin paraganglioma in man. Ann Otol Rhinol Laryngol* 1953;62:1045-71.
- 6) Suárez C, Sevilla MA, Llorente JL. *Temporal paragangliomas. Eur Arch Otorhinolaryngol* 2007;264(7):719-31.
- 7) Grover N, Amen F, Gallimore A, Brookes G. *External auditory canal paraganglioma: an atypical presentation. J Laryngol Otol* 2012;126(12):1278-80.
- 8) Kundu I, Goswami S, Barman D, Biswas S. *Paraganglioma of external auditory canal. Indian J Otolaryngol Head Neck Surg* 2001;53(4):304-6.
- 9) Woods CI, Strasnick B, Jackson CG. *Surgery for glomus tumors: the Otolaryngology Group experience. Laryngoscope* 1993;103(11 Pt 2 Suppl 60):65-70.
- 10) O'Leary MJ, Shelton C, Giddings NA, Kwartler J, Brackmann DE. *Glomus tympanicum tumors: a clinical perspective. Laryngoscope* 1991;101(10):1038-43.
- 11) Jackson CG. *Basic surgical principles of neurotologic skull base surgery. Laryngoscope* 1993;103(11 Pt 2 Suppl 60):29-44.
- 12) Tran LP, Grundfast KM and Selesnick SH. *Benign lesions of the external auditory canal. Otolaryngol Clin North Am* 1996;29(5):807-26.
- 13) Friedmann I. *Pathological lesions of the external auditory meatus: a review. J R Soc Med* 1990;83(11):34-7.
- 14) Choi SY, Kim YH. *Surgical removal of giant glomus tympanicum extending into the external auditory canal and mastoid without preoperative embolization; a case report. J Clinical Otolaryngol* 2016;27(1):121-6.