

## The Relationship between Vestibulocochlear Symptoms and Types of the Anterior Inferior Cerebellar Artery (AICA) Pathway in Cerebellopontine Angle

Minbum Kim, MD, Hosuk Chu, MD, Min Young Song,  
Sang Duck Lee, MD, PhD and Hee Nam Kim, MD, PhD  
*Hana ENT Hospital, Seoul, Korea*

### — ABSTRACT —

**Objectives** : Aims of this study are 1) to evaluate radiological characteristics of the anterior inferior cerebellar artery (AICA) using three-dimensional Fourier Transformation Constructive Interference in Steady State (3D-FT CISS) MR imaging, and 2) to investigate the relationship between types of AICA and auditory or vestibular symptom. **Materials and Methods** : This is a retrospective study. Forty-five adult patients, who presented with auditory symptom and/ or vestibular symptom of unknown etiology at an ENT hospital from April 2010 to August 2011, were studied. Using 3D-FT CISS images, AICA course was identified in all the patients (90 ears). The relationship was investigated between types of the AICA loop and vestibulocochlear symptom. **Results** : According to Chavda's classification, 55 type I loops, 24 type II loops and 11 type III loops of the AICA were observed. Only type III loops show a statistically significant association with ipsilateral hearing loss and tinnitus ( $p=0.0001$ ). According to Shelton's classification, 14 class A courses, 52 class B, 18 class C and 6 class D were observed. However, any significant relationship was not found between cochleovestibular symptoms and AICA types of class A through D. **Conclusion** : A significant relationship was found between AICA loop and auditory symptom, when it extends more than 50% of the length of IAC. In these patients, neurovascular compression of vestibulocochlear nerve could be considered as a possible cause of hearing deterioration and tinnitus. (*J Clinical Otolaryngol 2012;23:74-78*)

**KEY WORDS** : Anterior inferior cerebellar artery (AICA) · Vestibulocochlear nerve · Neurovascular compression.

### Introduction

Since Jannetta first reported the result of microvascular decompression for vertigo in 1975, many studies on neurovascular compression (NVC) of vestibulocochlear nerve have been reported. Several vessels have been described as causing NVC. Anterior infe-

rior cerebellar artery (AICA) is the most interesting among them, because it is most commonly implicated in nerve compression and, in its normal course, runs in close proximity.<sup>1)</sup> However, since it has been demonstrated by cadaveric and radiologic studies that AICA approaches and even enters in internal auditory canal (IAC) in some asymptomatic individuals, controversy is still present.<sup>2,3)</sup> While Chavda et al. had reported significant association with unilateral hearing loss and AICA loops in the IAC,<sup>3)</sup> Shelton et al. reported no hearing association of AICA course in the IAC but the specific AICA position between vestibulocochlear nerve and facial nerve.<sup>4)</sup> Aims of this study are 1) to evaluate radiological characteristics of AICA using three-dimensional Fourier Transforma-

논문접수일 : 2012년 3월 28일  
논문수정일 : 2012년 4월 20일  
심사완료일 : 2012년 5월 11일  
교신저자 : 김민범, 135-514 서울 강남구 역삼동 732-19  
하나이비인후과병원  
전화 : (02) 6925-1111 · 전송 : (02) 3452-1495  
E-mail : minbumkim78@gmail.com

tion Constructive Interference in Steady State (3D-FT CISS) MR imaging, and 2) to investigate the relationship between types of AICA and auditory or vestibular symptom.

## Materials and Methods

This is a retrospective study. Forty-five adult patients who presented with auditory symptom and/or vestibular symptom of unknown etiology were studied at an ENT hospital from April 2010 to October 2011. Using 3D-FT CISS images, AICA course was identified in all patients (90 ears), relationship was investigated between types of the AICA loop and vestibulocochlear symptom with the PACS system (Infiniti Co.) by an otologic surgeon.

Asymmetrical sensorineural hearing loss was defined as an interaural difference more than 20 dB in pure tone audiometry at any one frequency or 10dB at two or more consecutive frequencies. According to the diagnostic criteria of ‘Vestibular paroxysmia’,<sup>5,9,10</sup> vestibular symptom was defined as unexplained recurrent vertigo spells lasting seconds to minutes and vestibular deficient side was decided by various vestibular function tests including positioning, positional, head shaking, hyperventilation and caloric test. Patients did not fulfill the criteria of established vestibular disorders such as Meniere’s disease, benign paroxysmal positional vertigo (BPPV), or vestibular neuritis.

Fisher’s exact test was used to compare the patients who has vestibulocochlear symptom and those who did not. A *p*-value of less than 0.01 was considered sta-

tistically significant.

## Results

All 90 ears were classified by two different classification systems.

According to Chavda’s classification,<sup>3</sup> AICA pathways were classified into three groups (Fig. 1). Type I loops, running within cerebellopontine angle (CPA) but not entering IAC, were observed in 55 ears (61%). Type II loops, entering IAC but not extending more than 50% of the length of IAC, were in 24 ears (27%). Type III loops, entering and also extending more than 50% of the length of IAC, were in 11 ears (12%).

According to Shelton’s classification,<sup>4</sup> AICA courses were categorized into four classes (Fig. 2). Class A course, in which AICA runs without contact to nerve, was observed in 14 ears (16%). Class B course, running adjacent to nerve, was in 52 ears (58%). Class C course, running between facial nerve and vestibulocochlear nerve, was in 18 ears (20%). Class D course, in which AICA loop displaces the nerve, was in 6 ears (7%).

And we analyzed the relationship between cochleovestibular symptoms and AICA types classified by Chavda’s criteria (Table 1). In the ears with type I and II AICA loops, no significant relationship was found between ipsilateral sensorineural hearing loss and AICA types. However, hearing loss was observed more frequently in the ears with type III loops (10/11, Fisher’s exact test, *p*=0.0001). As like hearing loss, tinnitus was more frequent in the ears with type III

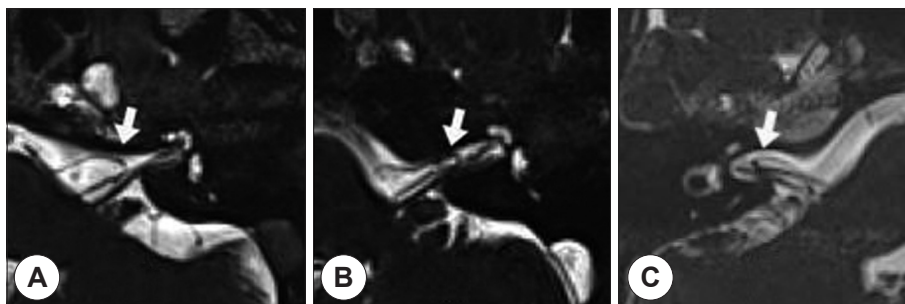
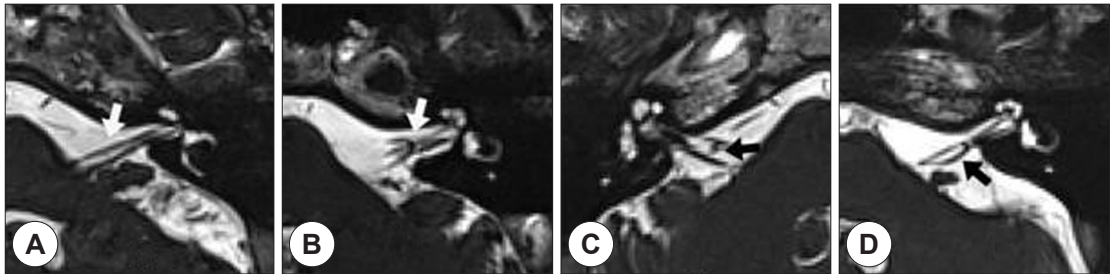


Fig. 1. Chavda’s classification of anterior inferior cerebellar artery loops. A : type I loop. B : type II loop. C : type III loop.

loops (10/11, Fisher's exact test,  $p=0.0001$ ), but not in the ears type I and II loops. However, no significant relationship was found between vertigo symptom and all three AICA types (Fisher's exact test,  $p>0.01$ ).

Next, we analyzed the relationship between cochleovestibular symptoms and AICA types classified by Shelton's criteria (Table 2). Any significant relationship was not found between vestibulocochlear symp-



**Fig. 2.** Shelton's classification of anterior inferior cerebellar artery courses. A: Class A course. B: Class B course. C: Class C course. D: Class D course.

**Table 1.** Relationship between vestibulocochlear symptoms and type of AICA loops according to Chavda's classification

Hearing loss	Type I (n=55)	Type II (n=24)	Type III (n=11)
Symptomatic	7	8	10*
Asymptomatic	48	16	1
*( $p=0.0001$ )			
Tinnitus	Type I (n=55)	Type II (n=24)	Type III (n=11)
Symptomatic	7	8	10*
Asymptomatic	48	16	1
*( $p=0.0001$ )			
Vertigo	Type I (n=55)	Type II (n=24)	Type III (n=11)
Symptomatic	4	5	4*
Asymptomatic	51	19	7
*( $p=0.02$ )			

**Table 2.** Relationship between vestibulocochlear symptoms and type of AICA loops according to Shelton's classification

Hearing loss	Class A (n=14)	Class B (n=52)	Class C (n=18)	Class D (n=6)
Symptomatic	4	14	6	1
Asymptomatic	10	38	12	5
( $p > 0.05$ )				
Tinnitus	Class A (n=14)	Class B (n=52)	Class C (n=18)	Class D (n=6)
Symptomatic	4	14	6	1
Asymptomatic	10	38	12	5
( $p > 0.05$ )				
Vertigo	Class A (n=14)	Class B (n=52)	Class C (n=18)	Class D (n=6)
Symptomatic	2	7	3	2
Asymptomatic	12	45	15	4
( $p > 0.05$ )				

toms and AICA types in ears with class A through D (Fisher's exact test,  $p > 0.05$ ).

Out of all AICA types, only type III loops showed a statistically significant association with ipsilateral hearing loss and tinnitus in our study.

## Discussion

Since the concept of vascular compression of cranial nerve was first suggested as a cause of clinical symptoms in 1934, numerous studies have been performed to investigate neurovascular compression syndrome (NVC). NVC causing trigeminal neuralgia, hemifacial spasm and glosso-pharyngeal neuralgia has been well described.<sup>1)</sup> Recently, this concept is further extended to involve the eighth (8th) cranial nerve. The hypothesis of demyelination and ephaptic transmission between denuded nerve fibers are thought to be the most likely pathogenesis of vestibulocochlear NVC, however, there is neither specific pathognomic sign nor diagnostic test yet.<sup>5-8)</sup>

Vestibulocochlear neurovascular compression can present single or multiple symptoms such as hearing loss, tinnitus and vertigo.

As for hearing loss, controversy is still present. A prospective study showed a significant association with ipsilateral hearing loss and AICA loops in internal auditory canal (166 out of 252 ears), using 3D-FT CISS MR images.<sup>3)</sup> In contrast, another study reported no significant association between them (10 out of 22 ears), however, conventional T2-weighted MR images were used in this report.<sup>4)</sup> In terms of vertigo, the specific criteria has been used to diagnose this disorder as vestibular paroxysmia in some groups, and some even reported this accounts for 4% of all patients with dizziness in a dizziness unit.<sup>9,10)</sup> About tinnitus, though some paroxysmal cases were reported, the relationship between tinnitus and AICA pathway is still unclear.<sup>6,7)</sup>

As radiologic technique improves, it becomes to achieve high resolution images of neurovascular structure in CPA. Three dimensional FT CISS image was

used to identify AICA pathway in our study. This sequence can provide good contrast between CSF and cranial nerve and allow for exact measurement of both normal anatomy and abnormality, compared to routine spin-echo images.<sup>11)</sup> Using this sequences, we could clearly trace AICA loops in all the ears.

At present, it is not possible to diagnose NVC based on MRI findings alone, due to limited evidence, despite of a significant association in our study. The lack of reliable diagnostic features and the presence of neurovascular contact in non-symptomatic patients makes clinicians hesitate to diagnose vestibulocochlear NVC.<sup>2-4,8)</sup> However, many studies on functional anatomy of cochleovestibular nerve and good surgical results of microvascular decompression supported the concept of vestibulocochlear NVC.<sup>7,8,12)</sup> Further prospective study about long term hearing in the suspicious patients and large-sized controlled study is necessary to make the role of NVC clearer.

## Conclusion

A significant relationship was found between the AICA type and auditory symptom when it extends more than 50% of the length of IAC. In these patients, neurovascular compression of vestibulocochlear nerve could be considered as a possible cause of hearing deterioration and tinnitus.

## REFERENCE

- 1) Yap L, Pothula VB, Lesser T. *Microvascular decompression of vestibulocochlear nerve. Eur Arch Otorhinolaryngol* 2008;265(8):861-9.
- 2) De Carpentier J, Lynch N, Fisher A, Hughes D, Willatt D. *MR imaged neurovascular relationships at the cerebellopontine angle. Clin Otolaryngol Allied Sci* 1996;21(4):312-6.
- 3) McDermott AL, Dutt SN, Irving RM, Pahor AL, Chavda SV. *Anterior inferior cerebellar artery syndrome: fact or fiction. Clin Otolaryngol Allied Sci* 2003;28(2):75-80.
- 4) Gorrie A, Warren FM 3rd, de la Garza AN, Shelton C, Wiggins RH 3rd. *Is there a correlation between vascular loops in the cerebellopontine angle and unexplained unilateral hearing loss? Otol Neurotol* 2010;31(1):48-52.
- 5) Mehmet K. *Vascular Vertigo: epidemiology and clinical syndromes. Neurologist* 2011;17(1):1-10.

- 6) Krister B. *Paroxysmal staccato tinnitus: a carbamazepine responsive hyperactivity dysfunction symptom of the eighth cranial nerve.* *J Neurol Neurosurg Psychiatry* 2010;81(4): 451-5.
- 7) De Ridder D, Moller AR, Nowe V, Ryu H, Van de Heyning P, Verlooy J. *Functional anatomy of the human cochlear nerve and its role in microvascular decompressions for tinnitus.* *Neurosurgery* 2004;54(2):381-8.
- 8) Ryu H, Nishizawa S, Nozue M, Sugiyama K. *Neurovascular compression syndrome of the eighth cranial nerve. Can the site of compression explain the symptoms?* *Acta Neurochir* 1999;141(5):495-501.
- 9) Brandt T, Dieterich M. *Vestibular paroxysmia: vascular compression of the eighth nerve?* *Lancet* 1994;343(8900): 798-9.
- 10) Hufner K, Barresi D, Glaser M, Linn J, Brandt T, Strupp M, et al. *Vestibularparoxysmia: diagnostic features and medical treatment.* *Neurology* 2008;71(13):1006-14.
- 11) Caselman JW, Kuhweide R, Deimling M. *Constructive interference in steady state 3DFT MR imaging of inner ear and cerebellopontine angle.* *AJNR Am J Neuroradiol* 1993;14(1):47-57.
- 12) Muller M, Muller A, Jannetta P, Jho H, Sekhar LN. *Microvascular decompression of the eighth nerve in patients with disabling positional vertigo: selection criteria and operative results in 207 patients.* *Acta Neurochir* 1993;125(1-4):75-82.