

레이저를 이용한 비내 수술 후 양측 사골동에 발생한 점액낭종 1례

김현규 · 구수권 · 한철우 · 김태헌

A Case Report of Bilateral Ethmoid Sinus Mucocoeles that were Formed after Intranasal Surgery Using Laser

Hyun-Kyu Kim, MD, Soo-Kweon Koo, MD, Cheol-Woo Han, MD and Tae-Heon Kim, MD

Department of Otolaryngology-Head and Neck Surgery, St. Benedict Hospital, Busan, Korea

-ABSTRACT-

Paranasal sinus mucocoeles are benign diseases that are formed by chronic inflammation, nasal polyps, adhesion after surgery, tumors, trauma etc. that obstruct the paranasal sinus orifices or lesser salivary glands orifices which cause mucous flow to be pooled, causing expansion, focal bone destruction and increase in pressure in the surrounding tissue. Treatment is done by radical therapy by total removal of the polyp or by conservative care by post-op marsupialization and orifice maintenance, the latter being performed more often by endoscopy. Recently, surgery using lasers are being performed more often because the laser does not touch the excision site, so the operative field of view is not blocked by the surgical equipment, and bleeding control is possible with the removal of the tissue. However, lasers have the side effect of damaging the tissue with heat, forming scars around the surgery site. We have recently experienced one case of bilateral ethmoid sinus mucocoeles that were formed after intranasal surgery using laser in private practices. Endoscopic sinus surgery was performed under local anesthesia for mucocoele marsupialization. (J Clinical Otolaryngol 2005;16:320-322)

KEY WORDS : Mucocoele · Endoscopy · Laser surgery.

서 론

1)4)

가

1-3)

: 2005 8 29

: 2005 9 10

: , 602 - 739

3

증 례

31 - 3

: (051) 466 - 7001 · : (051) 464 - 7271

E - mail : chief123@chol.com

41

2

:

1

(Fig. 2). 2

1

가

(Fig. 1).

4

Fig. 1. Preoperative endoscopic finding of right nasal cavity (A) and left nasal cavity (B) shows laser induced scars in both middle turbinates (*) and polypoid change in the anterior wall of the anterior ethmoid sinus (+).

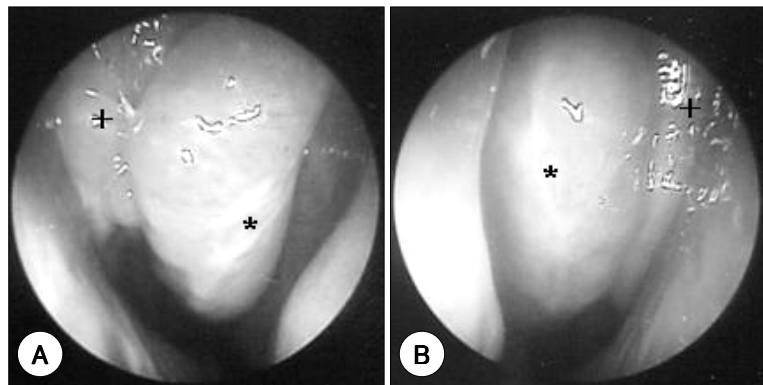


Fig. 2. Magnetic resonance image in axial plane. A : Axial section of T1-weighted image ; homogenous low signal density mass in bilateral ethmoid sinus. B : Axial section of T2-weighted image ; homogenous high signal density mass in bilateral ethmoid sinus.

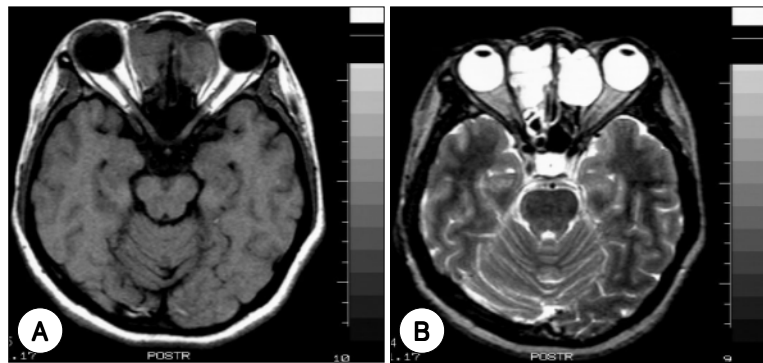
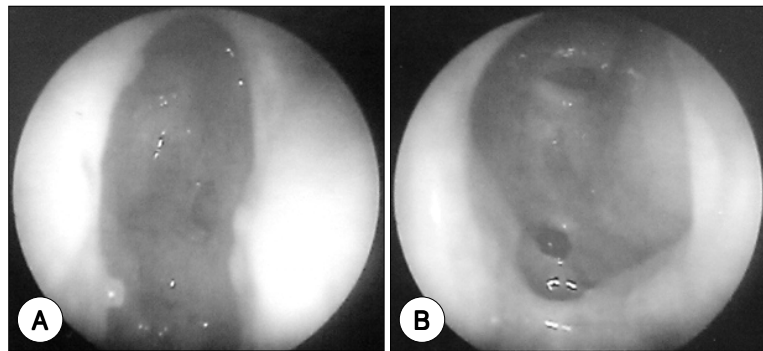


Fig. 3. Postoperative endoscopic finding of right nasal cavity (A) and left nasal cavity (B) shows that the site of marsupialization was maintained with good patency and there was no purulent discharge.



(Fig. 3).
 고 찰
 1-4)
 가
 가
 4-6)
 가
 가
 1-2
 가
 가
 1)2)
 가
 중심 단어 :
 가

5)
 X -
 , CT
 가가
 가
 4)7) MRI CT
 T1, T2 - weighted image
 T1
 , T2
 8)9)

REFERENCES

- 1) Kwon SA, Jeong WC. Endoscopic surgery for paranasal sinus mucocoeles. *Korean J Otolaryngol* 1997;40:1431-6.
- 2) Lee KC, Kwon KH, Kang HG, Jin SM, Lee YB. Endoscopic sinus surgery in paranasal sinus mucocoeles. *Korean J Otolaryngol* 1997;40:855-60.
- 3) Beasley NJ, Jones NS. Paranasal sinus mucocoele: Modern management. *Am J Rhinol* 1995;9:251-6.
- 4) Kennedy DW, Josephson JS, Zinreich J. Endoscopic sinus surgery for mucocoeles: A viable alternative. *Laryngoscope* 1989;99:885-95.
- 5) Evans C. Aetiology and treatment of frontoethmoidal mucocoele. *J Laryngol Otol* 1981;95:361-75.
- 6) Toriumi DM. Multiple frontoethmoid mucocoeles. *Ann Otol Rhinol Laryngol* 1989;98:831-3.
- 7) Chui MC, Briant TD, Gray T, Horsey WJ, Hudson AR, Tucker W. Computed tomography of sphenoid sinus mucocoele. *J Otolaryngol* 1983;12:263-9.
- 8) Lee WS, Hwang JY, Chung DH, Eom SK. Clinical experiences with a case of sphenoid sinus mucocoele. *Korean J Otolaryngol* 1992;35:143-7.
- 9) Stankiewicz JA. Sphenoid sinus mucocoele. *Arch Otolaryngol Head Neck Surg* 1989;115:735-40.