

상하 회전 가능한 전자 후두내시경의 개발

왕수건¹ · 노정훈² · 이병주¹ · 이진춘¹ · 전계록²
이상권³ · 박찬흠⁴ · 옥정환⁵ · 김태석⁶

Development of Semiflexible Digital Laryngoscope

Soo-Geun Wang, MD¹, Jung Hoon Ro, PhD², Byung-Joo Lee, MD¹,
Jin-Choon Lee, MD¹, Gye-Rok Jeon, PhD², Sang-Kwon Lee, MD³,
Chan-Hum Park, MD⁴, Jeong-Hwan Ok⁵ and Tae-Seok Kim⁶

¹Department of Otolaryngology, ²Biomedical Engineering and ³Thoracic and Cardiovascular Surgery,
College of Medicine, Pusan National University, Busan, ⁴Department of Otolaryngology, College of Medicine,
Hallym University, Chuncheon, ⁵NGC IT Ltd, Seoul, ⁶Sunkwang Electronics Co., Ltd, Seoul, Korea

- ABSTRACT -

Purpose : Laryngoscope is a basic equipment for examining the laryngopharynx. The pre-existing rigid laryngoscopes and fiberscopes have some inconvenience. The problems of the current rigid laryngoscopes are as follows : 1) absence of biopsy channel, 2) difficulties in exposing the larynx in cases of severe gag reflex, short neck, and children, 3) very vulnerable, 4) relatively high cost, and 5) not portable. In addition, disadvantages of the fiberscopes are as follows : 1) sometimes it is difficult to fix the tip to evaluate the lesion, especially in oropharynx, and nasopharynx, 2) very high cost, 3) frequent Moire sign (+), and 4) not portable. Authors have developed a portable digital rigid laryngoscope with flexible head for replacing the pre-existing rigid telescope and fiberscope. **Methods and Materials** : Recently developed high luminescent white LEDs (light emitting diodes) are placed at the head of the endoscope as a light source for the CCD image sensor which is also placed at the head with imaging lenses. This arrangement eliminates the bulky light sources like halogen or xenon lamps as well as the expensive light guiding optical fibers. We adopted non-spherical lens system to prevent peripheral image distortion and Moire sign, and to enhance depth of field. In addition, it can be bent not only to downward but also to upward upto 130°. **Results** : The advantages of portable digital rigid laryngoscope demonstrated as following : 1) Not only the laryngopharynx but also the nasopharynx, oral cavity, and oropharynx could be observed 2) The laryngopharyngeal pathologic lesion could be biosied through biopsy channel, 3) The laryngeal pathology can be easily removed because the flexible part is supported firmly through the combined rigid part. In case of poor laryngeal exposure through suspension laryngoscopy, it can also be easily removed through biopsy channel. 4) it can be checked the air leakage using air pump. **Conclusion** : Portable digital rigid laryngoscope with rigid body and flexible head has a lot of advantage over simple fiberscope or rigid laryngoscope. It is a very useful equipment especially for otorhinolaryngologists. In addition, it can be applied for thoracoscope, laparoscope, cystourethroscope, colposcope, etc. (J Clinical Otolaryngol 2005;16:275-280)

KEY WORDS : Digital · Semiflexible laryngoscope.

: 2005 10 1
: 2005 10 27
: , 602 - 739 171 10
: (051)240 - 7533 · : (051)242 - 5003 E - mail : jhro@pusan.ac.kr

서론

가
가
가
1854 Garcia
(dental mirror)
(hand mirror)
. ¹⁾ 3 1857 Türch
(hand mirror)
1907 Brunnings (direct laryngoscope)
²⁾ 1912 Killian (suspension laryngoscopy)
³⁾ 1966 Taub⁴⁾ (rigid telarlaryngoscope)
Sawashima Hirose 1968 (flexible fiberoptic laryngoscope)
⁵⁾

(peripheral distortion)

(Moire sign)

가

가

가

연구방법

Fig. 1

(light emitting diode)

1/4 CCD(charge - coupled device)
(Sony, ICX226AK) CMOS(complementary metal - oxide semiconductor) (sensor)
(aspherical lens)
(aspherical lens)
30~130 mm (depth of field)
90 ° (angle of view) 가

가
가
가
(biopsy channel)
가 가
가 가

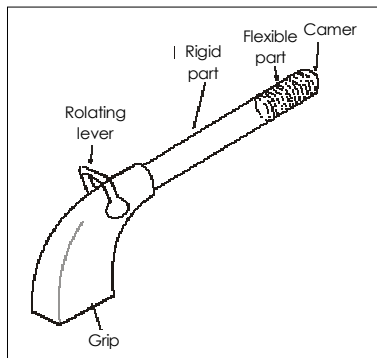


Fig. 1. Appearance of the semi-flexible digital laryngoscope. Bending upward as well as downward is possible.

(image plane) 5.5 mm
 LED 가 1.2 cd
 , 12 cm 80 lux
 (focal ratio, F number) 8 (pin hole) 가 4
 LED (Fig. 2).

가
 가
 130°
 (Fig. 3).

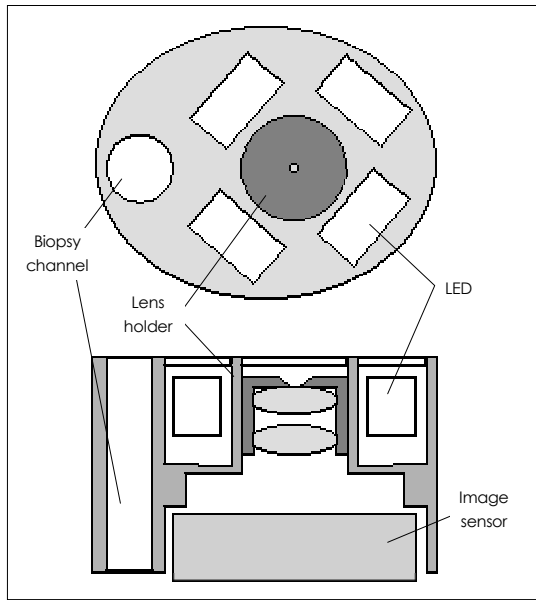


Fig. 2 . Schematic view of image acquisition part. Plane view from upward (a) and cross sectional view from side (b). Up to four LEDs could be used for sufficient luminescence. A biopsy channel is prepared and all the upper plane is covered with sapphire windows.

가
 가
 (biopsy channel)

(Radio Frequency)

결 과

1) 가

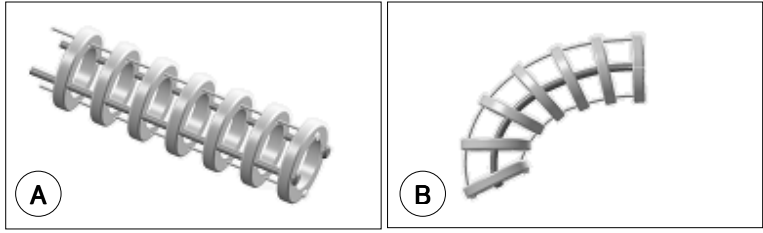


Fig. 3. The assembly of rings connected through two elastic side wires and two sliding upper and lower wirings (a) and a bent appearance of the assembly by pulling the lower wiring.

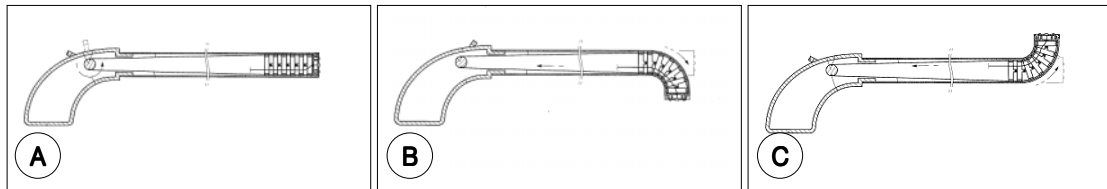


Fig. 4. The motions of rotating lever and flexible parts of the semi-flexible digital laryngoscope. A : forward for oropharynx, B : downward for laryngopharynx, C : upward for nasopharynx.

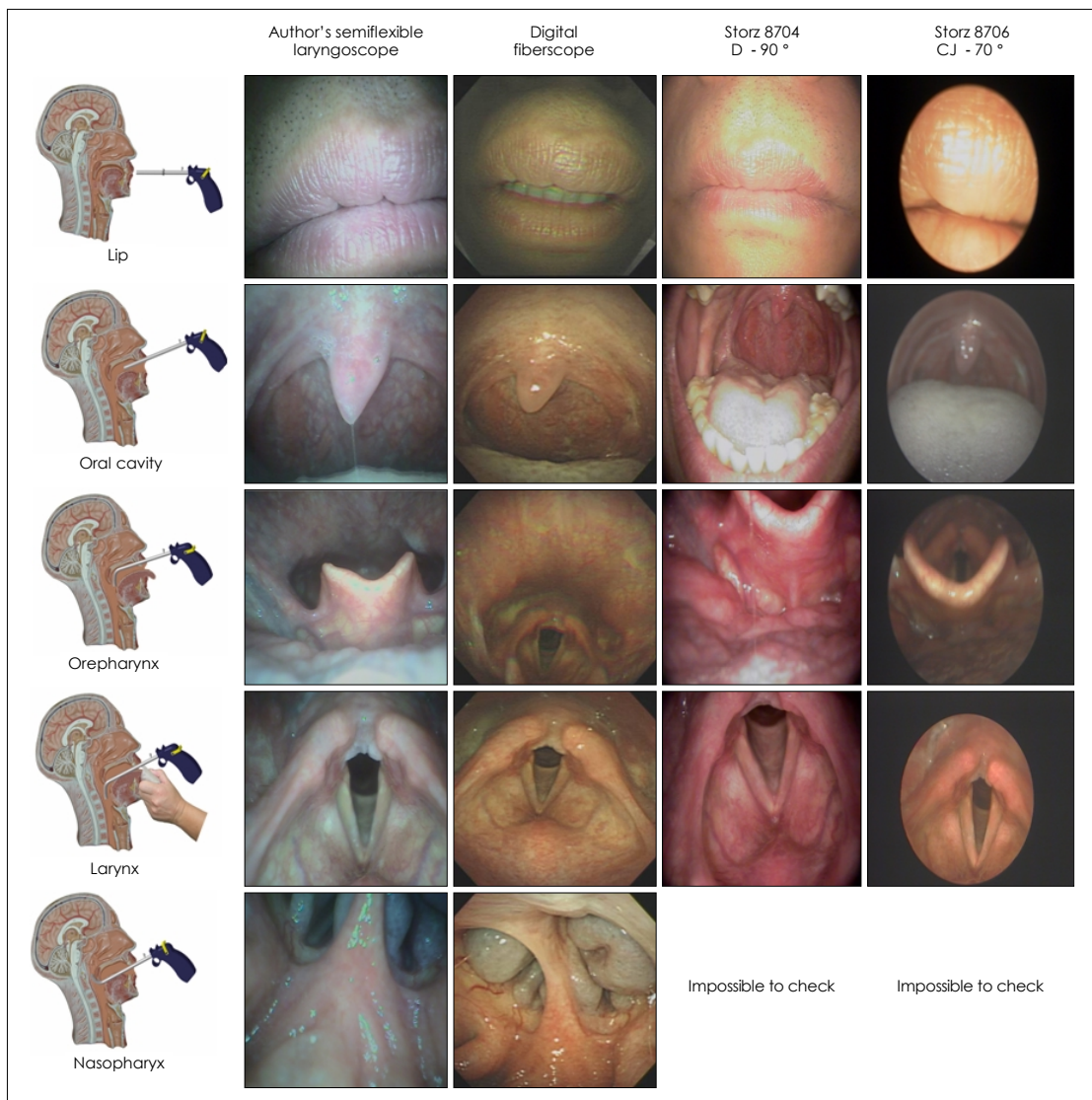


Fig. 5. Comparison of local findings between various types of laryngoscope and the author's semi-flexible digital laryngoscope.

가 , 가 가

(Fig. 4C) (Fig. 4B) (Fig. 4A),

가

2) 가 ,

3) 가 가 ,

90 , 70

가

(Fig. 5).

4) (direct laryngoscope) 가 , 가

가 Kawaida¹³⁾ (electronic videoendoscope) CCD (sensor) , (fiberoptic flexible laryngoscope)

가

(wide angle lens) 가

(laryngeal stroboscopy), (ultra high speed digital imaging technique),⁶⁾ (glottography),⁷⁾ (videokymography),⁸⁾ (videostrobokymography),⁹⁾ (glottography) (electroglottography, EGG)¹¹⁾ (photoelectroglottography)¹²⁾ (ultrasound glottography)¹⁰⁾¹²⁾ 가 가 가

가 Tsunoda 가 mini DV

가 , 가 CCD

가 , 가 Omori 가¹⁴⁾ 가 (forceps) (vocal

가 , 가 polyp) (granuloma)

(Rienke's edema) 가 가
 15) . 가 가
 가 가
 가 .
 가 ' ' '
 가 .
결 론
 가 가
 가 가

중심 단어 :

REFERENCES

1) Garcia M *Observations on the human voice. Philos Mag and J of Sci* 1855;10:218-26.
 2) Brunnings W. *Direct laryngoscopy, bronchoscopy, and esophagoscopy.* London: Bailliere, Tindall. & Cox;1912. p.110-5.
 3) Killain G. *Die Schwelaryngoskopie. Arch Laryngol Rhinol* 1912;26:277-317.

4) Taub S. *The Taub oral panendoscope: a new technique. Cleft Palate J* 1966;3:328-46.
 5) Sawashima M, Hirose H. *New laryngoscopic technique by use of fiber optics. J Acoust Soc Am* 1968;43:168-9.
 6) Kiritani S, Hirose H, Imagawa H. *High-speed digital image recording system for observing vocal fold vibration using an image sensor. Iyodenshi To Seitai Kogaku* 1987; 25:284-90.
 7) Gall V. *Strip kymography of the glottis. Arch Otorhinolaryngol* 1984;240:287-93.
 8) Svec JG, Schutte HK. *Videokymography: high-speed line scanning of vocal fold vibration. J Voice* 1996;10:201-5.
 9) Sung MW, Kim KH, Koh TY, Kwon TY, Mo JH, Choi SH et al. *Videosrobokymography: A new method for the quantitative analysis of vocal fold vibration. Laryngoscope* 1995;109:1895-63.
 10) 山本公一, 角田篤信. 喉頭のビデオストスコピ. 耳鼻咽喉科, 頭頸部外科 MOOK23;1992. p.11-28.
 11) Gremy F, Striglion L. *Contribution to the study of the physiology of the of the larynx of thespeaking voice: contribution of electroglottography. Rev Laryngol Otol Rhinol (Bord).* 1963;84:399-408.
 12) Tsuchiya H. *Simultaneous recording of vocal cord vibrations by ultrasound laryngography and photoelectroglottography. Nippon Jibiinkoka Gakkai Kaiho* 1991;94: 895-905.
 13) Kawaida M, Fukuda H, Kohno N. *Observations of laryngeal lesions with a rhinolarynx electronic videoendoscope system and digital image processing. Ann Otol Rhinol Laryngol* 1998;107:855-9.
 14) Tsunoda A, Tsunoda R, Hatanaka A. *Endoscopic adaptor for digital camera and digital imaging filing. Laryngoscope* 2002;112:1308-9.
 15) Omori K, Shinohara K, Tsuji T, Kojima H. *Videoendoscopic laryngeal surgery. Ann Otol Rhinol Laryngol* 2000;109: 149-55.