

폐쇄성 수면 무호흡증의 폐쇄부위 평가

김정수 · 이규엽 · 송선희

The Evaluation of Obstruction Site in Patients with Obstructive Sleep Apnea

Jung Soo Kim, MD, Kyu Yup Lee, MD and Sun Hee Song, MD

Department of Otorhinolaryngology, College of Medicine, Kyungpook National University, Daegu, Korea

서 론

(fluoroscopy),
(cephalometry), (CT),
(MRI)

가

가

4%, 2%
3)4)

가
(base of tongue)
가⁵⁾

1)
2)
3)
4)
5)
6-9) Rojewski¹⁰⁾

가
(Fiberoptic Nasopharyngoscope)

가 , ,

11) 가
(velopharynx)¹²⁾

가

: , 700 - 721 2가 50

: (053) 420 - 5785 · : (053) 423 - 4524
E - mail : sookim@knu.ac.kr가
(forced inspiration)

: 가

수면 중 역동적 폐쇄부위 검사법

자기공명영상 (Magnetic Resonance Imaging)

가

가

가

가

가

가

²³⁾

가

수면 비인두 내시경(sleep nasoendoscopy)

, 3

가

(sequential study)

Johal ²⁹⁾

가 가

mandibular advancement splint

(motion artifact)

가

가

가 가

가 가

¹⁶⁾¹⁷⁾

Rodenstein ²⁴⁾

카테터(catheters)

(sagittal plane)

가

가

가

plane)

(coronal

Horner ²⁵⁾

가

가

가

³⁰⁾

(compliance)

투시검사(Fluoroscopy)

가 가

가 가

²⁶⁻²⁸⁾

초고속 자기공명영상(Ultrafast Magnetic Resonance Imaging)

가 Crumley
 5) ()
 31) 가
 전자선 단층촬영(Electron Beam Tomography)
 210
 가 가 가
 가 가 가
 20 4 2 Multi detector 컴퓨터 단층촬영(MD-CT)
 12 (detector ar-
 11 cm ray) 1
 가 12
 가
 5)32 - 34) 35) 3
 가
 가 가 가 MD-CT
 Stein 32)
 8 가 (simulated longitudinal diagram)
 (Fig. 1)

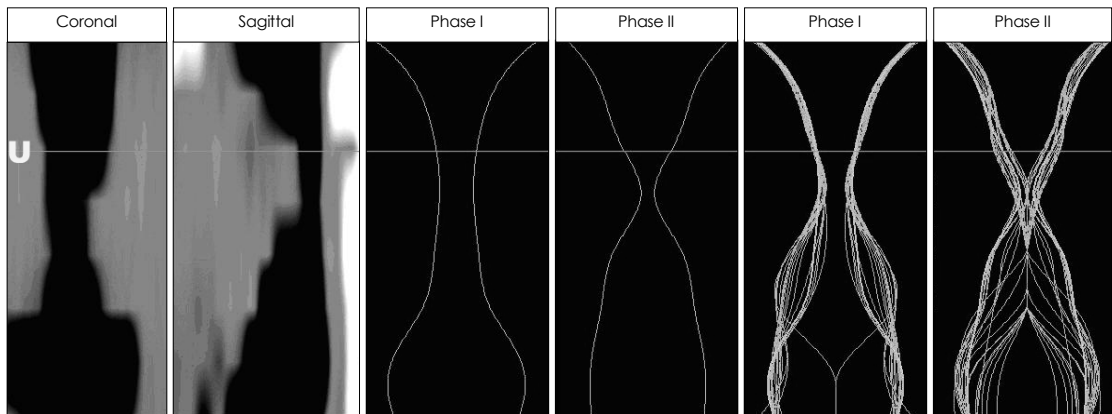


Fig. 1. The stimulated longitudinal display of the oropharynx showing the results of MD CT in awake and asleep states. Coronal : coronal scout view of oropharynx, sagittal : sagittal scout view of oropharynx, phase 1 : minimal cross sectional area of oropharynx during respiration in awake state, phase 2 : maximal cross sectional area of oropharynx in asleep state. The U (uvula) line means uvular levels of oropharynx.

MD - CT 20
 MD - CT가
 CT
 CT가
 36)
 가
 중심 단어 :

REFERENCES

- 1) Ingbar DH, Gee JB. *Pathophysiology and treatment of sleep apnea. Annu Rev Med* 1985;36:369-95.
- 2) Young T, Palta M, Dempsey J, Skatrud J, Weber S, Badr S. *The occurrence of sleep-disordered breathing among middle-aged adults. N Engl J Med* 1993 Apr 29;328(17):1230-5.
- 3) Ip MS, Lam B, Tang LC, Launder IJ, Ip TY, Lam WK. *A community study of sleep disordered breathing in middle-aged Chinese men in Hong Kong. Chest* 2001;119:62-9.
- 4) Ip MS, Lam B, Tang LC, Launder IJ, Ip TY, Lam WK. *A community study of sleep-disordered breathing in middle-aged Chinese women in Hong Kong: prevalence and gender differences. Chest* 2004 Jan;125(1):127-34.
- 5) Crumley RL, Stein M, Gamsu G, Goldon J, Dermon S. *De-termination of obstructive site in obstructive sleep apnea.*

가

Laryngoscope 1987;97:301-8.

- 6) Badr MS, Toiber F, Skatrud JB, Dempsey J. *Pharyngeal narrowing/occlusion during central sleep apnea. J Appl Physiol* 1995 May;78(5):1806-15.
- 7) Morrell MJ, Arabi Y, Zahn BR, Meyer KC, Skatrud JB, Badr MS. *Effect of surfactant on pharyngeal mechanics in sleeping humans: implications for sleep apnoea. Eur Respir J* 2002 Aug;20(2):451-7.
- 8) Suto Y, Matsuo T, Kato T, Hori I, Inoue Y, Ogawa S, Suzuki T, Yamada M, Ohta Y. *Evaluation of the pharyngeal airway in patients with sleep apnea: value of ultrafast MR imaging. Am J Roentgenol* 1993 Feb;160(2):311-4.
- 9) Woodson BT, Wooten MR. *Comparison of upper-airway evaluations during wakefulness and sleep. Laryngoscope.* 1994 Jul;104(7):821-8.
- 10) Rojewski TE, Schuller DE, Clark RW, Schmidt HS, Potts RE. *Synchronous video recording of the pharyngeal airway and polysomnograph in patients with obstructive sleep apnea. Laryngoscope.* 1982 Mar;92(3):246-50.
- 11) Remmers JE, Launois S, Feroah T, Whitelaw WA. *Mechanics of the pharynx in patients with obstructive sleep apnea. Prog Clin Biol Res* 1990;345:261-8.
- 12) Isono S, Remmers JE, Tanaka A, Sho Y, Sato J, Nishino T. *Anatomy of pharynx in patients with obstructive sleep apnea and in normal subjects. J Appl Physiol* 1997 Apr;82(4):1319-26.
- 13) Goldberg AN, Schwab RJ. *Identifying the patient with sleep apnea: upper airway assessment and physical examination. Otolaryngol Clin North Am.* 1998 Dec;31(6):919-30.
- 14) Rama AN, Tekwani SH, Kushida CA. *Sites of obstruction in obstructive sleep apnea. Chest* 2002 Oct;122(4):1139-47.
- 15) Schwab RJ, Goldberg AN. *Upper airway assessment: radiographic and other imaging techniques. Otolaryngol Clin North Am* 1998 Dec;31(6):931-68.
- 16) Strelzow VV, Blanks RH, Basile A, Strelzow AE. *Cephalometric airway analysis in obstructive sleep apnea syndrome. Laryngoscope* 1988 Nov;98(11):1149-58.
- 17) Tsuchiya M, Lowe AA, Pae EK, Fleetham JA. *Obstructive sleep apnea subtypes by cluster analysis. Am J Orthod Dentofacial Orthop* 1992 Jun;101(6):533-42.
- 18) Suratt PM, Dee P, Atkinson RL, Armstrong P, Wilhoit SC. *Fluoroscopic and computed tomographic features of the pharyngeal airway in obstructive sleep apnea. Am Rev Respir Dis* 1983 Apr;127(4):487-92.
- 19) Walsh JK, Katsantonis GP, Schweitzer PK, Verde JN, Muehlbach M. *Somnofluorography: cineradiographic observation of obstructive sleep apnea. Sleep* 1985;8:294-7.
- 20) Pepin JL, Ferretti G, Veale D, Romand P, Coulomb M, Brambilla C, et al. *Somnofluorography, computed tomography, and cephalometry in the assessment of the airway in obstructive sleep apnoea. Thorax* 1992;47:150-6.
- 21) Katsantonis GP, Walsh JK. *Somnofluorography: its role in the selection of candidates for uvulopalatopharyngoplasty. Otolaryngol Head Neck Surg* 1986 Jan;94(1):56-60.
- 22) Horner RL, Shea SA, McIvor J, Guz A. *Pharyngeal size and shape during wakefulness and sleep in patients with obstructive sleep apnoea. Q J Med* 1989 Aug;72(268):719-35.

- 23) Ryan CF, Lowe AA, Li D, Fleetham JA. *Magnetic resonance imaging of the upper airway in obstructive sleep apnea before and after chronic nasal continuous positive airway pressure therapy. Am Rev Respir Dis 1991 Oct; 144(4):939-44.*
- 24) Rodenstein DO, Doms G, Thomas Y, Liistro G, Stanescu DC, Culee C, et al. *Pharyngeal shape and dimensions in healthy subjects, snorers, and patients with obstructive sleep apnoea. Thorax 1990 Oct;45(10):722-7.*
- 25) Horner RL, Mohiaddin RH, Lowell DG, Shea SA, Burman ED, Longmore DB, et al. *Sites and sizes of fat deposits around the pharynx in obese patients with obstructive sleep apnoea and weight matched controls. Eur Respir J 1989 Jul;2(7):613-22.*
- 26) Yokoyama M, Yamanaka N, Ishii H, Tamaki K, Yoshikawa A, Morita R, et al. *Evaluation of the pharyngeal airway in obstructive sleep apnea: study by ultrafast MR imaging. Acta Otolaryngol Suppl 1996;523:242-4.*
- 27) Yoshida K, Fukatsu H, Ando Y, Ishigaki T, Okada T. *Evaluation of sleep apnea syndrome with low-field magnetic resonance fluoroscopy. Eur Radiol 1999;9:1197-202.*
- 28) Ikeda K, Ogura M, Oshima T, Suzuki H, Higano S, Takahashi S, et al. *Quantitative assessment of the pharyngeal airway by dynamic magnetic resonance imaging in obstructive sleep apnea syndrome. Ann Otol Rhinol Laryngol 2001; 110:183-9.*
- 29) Johal A, Battagel JM, Kotecha BT. *Sleep nasendoscopy: a diagnostic tool for predicting treatment success with mandibular advancement splints in obstructive sleep apnoea. Eur J Orthod 2005 Jul 27; [Epub ahead of print]*
- 30) Rama AN, Tekwani SH, Kusida CA. *Sites of obstruction in obstructive sleep apnea. Chest 2002;122:1139-47.*
- 31) Yokoyama M, Yamanaka N, Ishii H, Tamaki K, Yoshikawa A, Morita R. *Evaluation of the pharyngeal airway in obstructive sleep apnea: study by ultrafast MR imaging. Acta Otolaryngol (Stockh) 1996;Suppl 523:242-4.*
- 32) Stein MG, Gamsu G, Geer G, Golden JA, Crumley RL, Webb WR. *Cine CT in obstructive sleep apnea. Am J Roentgenol 1987;148:1069-74.*
- 33) Eil SR, Jolles H, Galvin JR. *Cine CT demonstration of nonfixed upper airway obstruction. American Roentgen Ray Society 1986;146: 669-77.*
- 34) Burger CD, Stanson AW, Sheedy II PF, Daniels BK, Shepard JW. *Fast-computed tomography evaluation of age-related changes in upper airway structure and function in normal men. Am Rev Respir Dis 1992;145:846-52.*
- 35) Lee KY, Lee CM, Choi YJ, Lee YJ, Jung SS, Kim JS. *Comparison of electron beam tomography and multidetector computed tomography for dynamic upper airway study in snorers. J Rhinol 2004;11:57-61.*
- 36) Sohn JH, Choi YJ, Lee CM, Jang HY, Kim JH, Lee KY, et al. *Effects of the body position changes on upper airway caliber in obstructive sleep apnea during sleep. Korean J Otolaryngol 2005;48:1242-7.*