

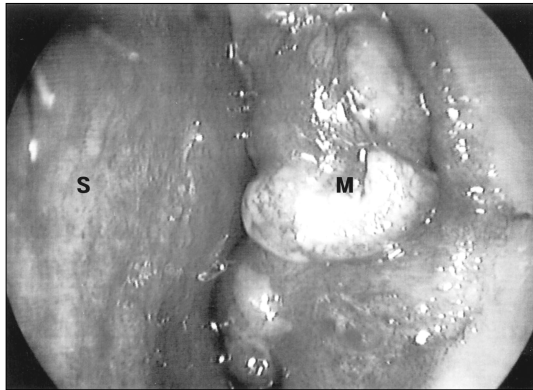Fig. 1. Preoperative endoscopic finding. An irregular surfaced pinkish mass arising from the left lateral nasal wall just behind the nasal vestibule is filling the anterior nasal cavity (S : nasal septum, M : mass).

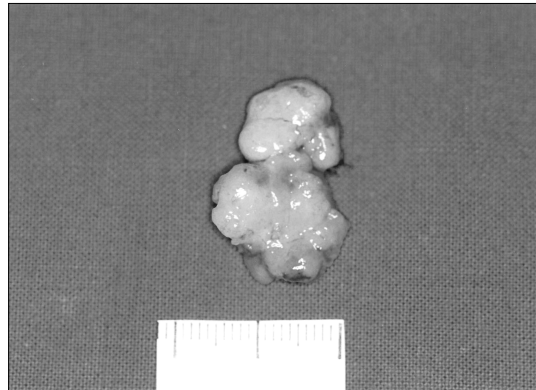

Fig. 3. Gross specimen finding. A yellowish mass measuring 2.0 x 1.5 x 1.0 cm is seen.

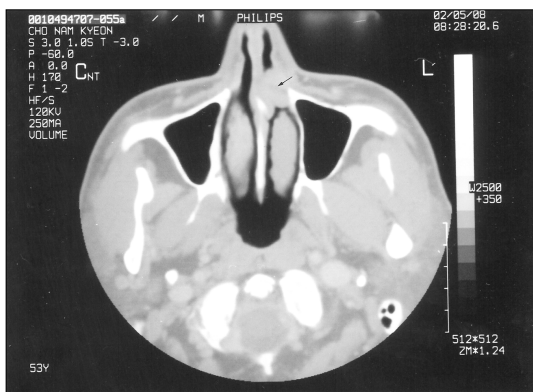

Fig. 2. Preoperative axial view of PNS CT. The well circumscribed mass with somewhat marginal enhancement is confined to the anterior left nasal cavity.

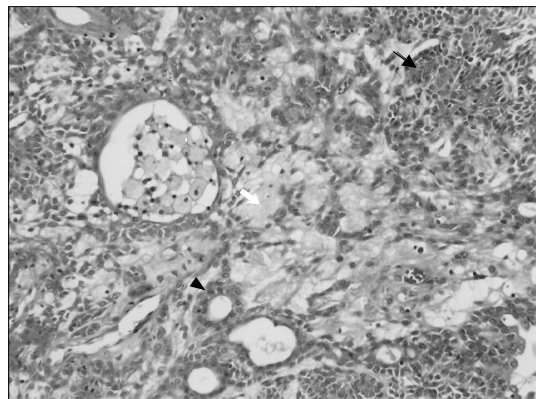


Fig. 4. Histopathologic finding of the mass showing abundant myxoid stroma with interspersed island of epithelial cells. white arrow : myxoid stroma, black arrow : epithelial cells, arrow head : ductal epithelial cell (H & E stain, x200).

1.5 x 1.0 cm
 (Fig. 3).
 가
 가
 (Fig. 4).
 2 2 6

고 찰
 가
 가
 10%
 2)

가 : 1

가

가

30 60

가

가

가

10%

1-3)

가

18 50

6)

2 5

가

4)

중심 단어 :

REFERENCES

- 1) Compago J, Wang RT. *Intranasal mixed tumors (Pleomorphic adenomas). A clinicopathologic study of the 40 cases. Am J Clin Path 1977;68:213-8.*
 - 2) Suzuki K, Moribe K, Bara S. *A rare case of pleomorphic adenoma of the lateral wall of the nasal cavity, with special reference of statistical observation of pleomorphic adenoma of the nasal cavity in Japan. Nippon Jibiinkoka Gakkai Kaiho 1990;93:740-5.*
 - 3) Wakami S, Muraoka M, Nakai Y. *Two cases of pleomorphic adenoma of the nasal cavity. Nippon Jibiinkoka Gakkai Kaiho 1996;99:38-45.*
 - 4) Prager DA, Weiss MH, Buchalter WL, Jacobs M. *Pleomorphic adenoma of the nasal cavity. Ann Otol Rhinol Laryngol 1991;100:600.*
 - 5) Cho KJ, El-Naggar AK, Mahanupab P, Luna MA, Batsakis JG. *Carcinoma ex-pleomorphic adenoma of the nasal cavity: a report of two cases. J Laryngol Otol 1995;109:677-9.*
 - 6) Unlu HH, Celik O, Demir MA, Eskiizmir G. *Pleomorphic adenoma originated from the inferior nasal turbinate. Auris Nasus Larynx 2003;30:417-20.*
 - 7) Choi EC, Kim KM, Yoon JH, Cho NH, Park YY. *Two cases of Benign Mixed Tumor on Nasal Septum. Korean J Otolaryngol 1989;32:1189-94.*
- 가
- 5)
- 6%
- 15
- 6)
- 10%
- 가
- 가
- (carcinoma ex - pleomorphic adenoma)
- 5)
- 가