

이개에 발생한 모기질종(Pilomatrixoma) 1예

이동훈 · 이준규 · 이재홍 · 조용범

A Case of Pilomatrixoma Originated from Auricle

Dong Hoon Lee, MD, Joon Kyoo Lee, MD, Jae Hong Lee, MD and Yong Bum Cho, MD

Department of Otolaryngology-Head and Neck Surgery, Chonnam National University Medical School,
Gwangju, Korea

-ABSTRACT-

Pilomatrixoma is a benign skin neoplasm that arises from hair follicle matrix. Pilomatrixoma is a common skin neoplasm in the pediatric population that is often misdiagnosed as other skin conditions. The most prevalent sites of pilomatrixoma in children are the head and neck. The typical presentation is a firm, slowly enlarging, freely mobile, well circumscribed subcutaneous nodule. The diagnosis can generally be made with a clinical examination. Imaging studies are not required unless symptoms or the location of the lesion warrant such diagnostic assessments. The treatment of choice is surgical excision, and the recurrence rate is low. We present a case of pilomatrixoma arising from the auricle, which was treated with surgical excision. (J Clinical Otolaryngol 2005; 16:154-156)

KEY WORDS : Pilomatrixoma.

서론

가

5)

가 6)

6

(hair follicle) 1)

1

1)4)

0.12%³⁾, Angelique 5)

증례

55 1 가

6 가 5

1 × 1 cm

: 2005 4 2

: 2005 5 23

: , 501 - 190 1 8

: (062) 220 - 6770 · : (062) 228 - 7743

E - mail : choyb@chonnam.ac.kr

(hemangioma) 가 (Fig. 1). 가
 가
 1.5 x 1.5 cm 가
 가
 1.7 x 1.5 x 1 cm 가
 (basaloid cell), (ghost cell),

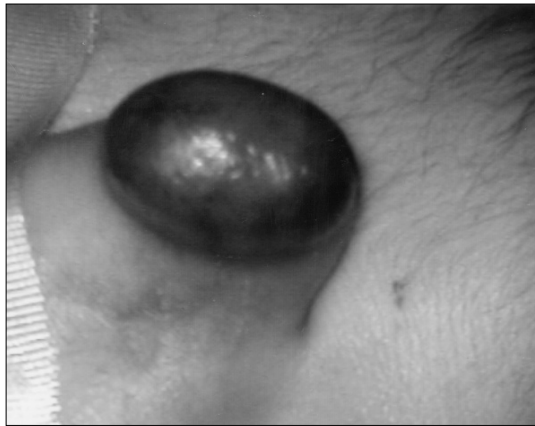


Fig. 1. Preoperative photograph. A 1.5 x 1.5 cm sized round dark brownish mass covered with skin is seen in left superior and posterior surface of auricle.

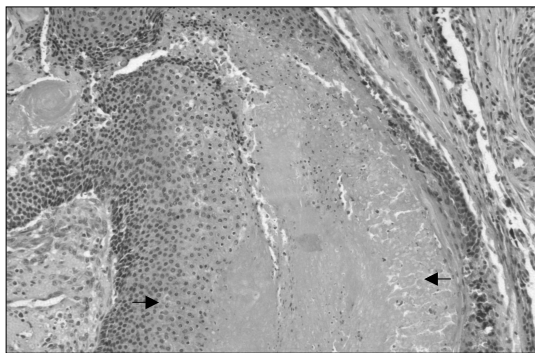


Fig. 2. Microscopic finding. Tumor composed of basaloid cell (black arrow) and ghost cell (white arrow) (H & E, x 100).

: (Pilomatrixoma) 1
 가 (Fig. 2).
 2
 6

고 찰

1880 Malherbe Chenantais
 (calcifying epithelioma of the sebaceous gland)
³⁾⁷⁾ 1949 Lever Griese-
 mer (hair matrix cell)
⁸⁾ 1961 Forbis Helwig⁹⁾

4)
 3)
 , 2 : 3
 10
 8-10)
 2% 26.7%
 3)9)17)
 Gardner syndrome, Sarcoido-
 sis, Steinert
 9)18-20)
 가

2)
 11)
 11)
 5)
 5)
 12)

가
5)
5)
5)
가
가
가 0% 6%
가
가
가
가
가
1
가

중심 단어 :

REFERENCES

- 1) Kwon KH, Kang IG, Yun JH, Hong SJ. Two Cases of Pilomatrixoma Originated from Auricle and Posterior Neck. *Korean J Otolaryngol* 2003;46:606-9.
- 2) Park JB, Kim MJ, Kang SN, Kim CA. Two Cases of Pilomatrixoma in Neck. *Korean J Otolaryngol* 2003;46:168-72.
- 3) Moehlenbeck FW. Pilomatrixoma (calcifying epithelioma). *Arch Dermatol* 1973;108:532-4.
- 4) Wells NJ, Blair GK, Magee JF, Whiteman DW. Pilomatrixoma: A common, benign childhood skin tumor. *Can J Surg* 1994;37:483-6.
- 5) Angelique DC, Samuel JL, Anthony H, Young HA, John M. Head and neck pilomatrixoma in children. *Arch Otolaryngol Head Neck Surg* 2001;127:1481-3.
- 6) Sloan JB, Sueki H, Jaworsky C. Pigmented malignant pilomatrixoma: Report of a case and review of the literature. *J Cutan Pathol* 1992;19:240-6.
- 7) Ravi PA, Steven DH. Pilomatrixoma of the head and neck in children. *Otolaryngol Head Neck Surg* 2001;125:510-5.
- 8) Mencia GE, Gutierrez DE, Garcia SE. Eyelid pilomatrixomas in young adults. *Cutis* 2002;69:23-6.
- 9) Forbis R, Helwig EB. Pilomatrixoma (calcifying epithelioma). *Arch Dermatol* 1961;83:606-18.
- 10) Taaffe A, Wyatt EH, Bury HP. Pilomatrixoma. A clinical and histopathological survey of 78 cases. *Int J Dermatol* 1988;27:477-80.
- 11) Jang HZ, Baik YG, Kim JM, Sohn JH. The study of the clinical and histopathological features of pilomatrixoma. *Korean J of Dermatol* 1997;35:693-701.
- 12) Orlando RG, Rogers GL, Bremer DL. Pilomatrixoma in a pediatric hospital. *Arch Ophthalmol* 1983;101:1209-10.
- 13) Toback JM, Hoover LA, Dudley JP. Pilomatrixoma of the head and neck. *Head Neck Surg* 1984;7:81-4.
- 14) Sasaki CT, Yue A, Enriques R. Giant calcifying epithelioma. *Arch Otolaryngol* 1976;102:753-5.
- 15) Jacobsen AS, Bowen J, Bruce J. The calcifying epithelioma of Malherbe in children: A 15 year experience. *Pediatr Surg Int* 1995;10:44-5.
- 16) Duflo S, Nicollas R, Roman S. Pilomatrixoma of the head and neck in children: A study of 38 cases and review of the literature. *Arch Otolaryngol Head Neck Surg* 1998;124:1239-42.
- 17) Demircan M, Balik E. Pilomatrixoma in children: A prospective study. *Pediatr Dermatol* 1995;12:331-5.
- 18) Urvoy M, Legall F, Toulemont PJ, Chevrand-Breton J. Pilomatrixomas multiples. *J Fr Ophthalmol* 1996;19:464-6.
- 19) McCulloch TA, Singh S, Cutton DW. Pilomatrix carcinoma and multiple pilomatrixomas. *Br J Dermatol* 1996;134:368-71.
- 20) Harper P. Calcifying epithelioma of Malherbe: Association with myotonic dystrophy. *Arch Dermatol* 1972;106:41-4.