

제 1 형 다발성신경섬유종과 동반된 접형골 형성부전 1 예

메리놀병원 이비인후과
권민상 · 김정근 · 권재환 · 조중환

A Case of Sphenoid Dysplasia Associated with Neurofibromatosis Type 1

Min Sang Kwon, MD, Jung Kean Kim, MD, Jae Hwan Kwon, MD and Joong Hwan Cho, MD
Department of Otorhinolaryngology-Head and Neck Surgery, Maryknoll General Hospital, Busan, Korea

-ABSTRACT-

Sphenoid dysplasia is rare and has reported to occur in 13.5% of patients with neurofibromatosis type 1 (NF-1). It is characterized by a defect in all or part of the greater wing, an elevation of the lesser wing of sphenoid, the distortion of the sella and the enlargement of the ipsilateral orbit. A 33-year-old man was admitted to our hospital with right zygomatic, maxillar fracture after trauma to right periorbital area. While treating the patient, pulsatile exophthalmos was found, and through computer tomographic scan, the absense of the wing of the sphenoid bone was found, along with the enlargement of the orbital cavity. He had skin problems since he was very young and a long history of decreased visual acuity in his right eye, but went untreated for them. After treating for the right zygomatic, maxillar fracture, and further discussion with the neurosurgery, he underwent sphenoid wing reconstruction with a number of surgicels and gelfoams. Postoperatively, his pulsating exophthalmos was not seen. We report successful treatment of sphenoid dysplasia associated with neurofibromatosis type 1. (J Clinical Otolaryngol 2004;15:303-306)

KEY WORDS : Sphenoid bone · Neurofibromatosis 1 · Exophthalmos.

서 론

1 (NF - 1)
(pathognomic) .¹⁾²⁾

³⁾

NF - 1

가

증 례

: 2004 9 18

: 2004 11 23

: , 600 - 730

33

가

4가

12

: (051) 461 - 2205 · : (051) 461 - 0297

E - mail : kwonms78@hanmail.net

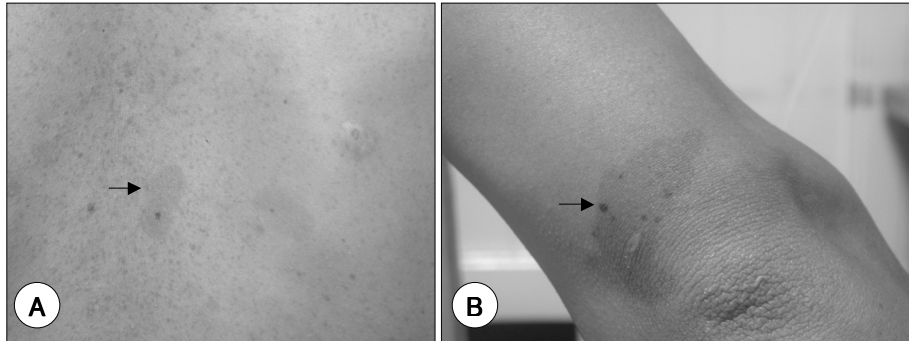


Fig. 1. Photography of cafe-au-lait-spot. A : on back, B : on elbow joint.

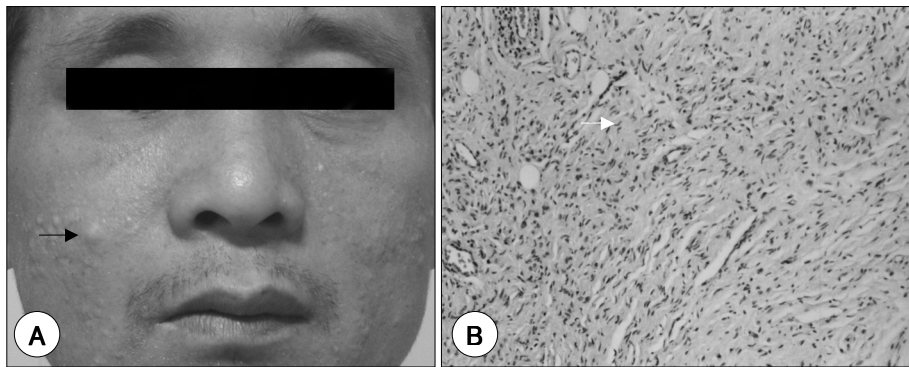


Fig. 2. A : Neurofibromas on right cheek of patient (arrow). They were biopsied for histologic examination, B : Section shows interacting bundles of elongated cells having wavy dark-staining nuclei (white arrow) and collagen-rich stroma (x 100, H-E stain).

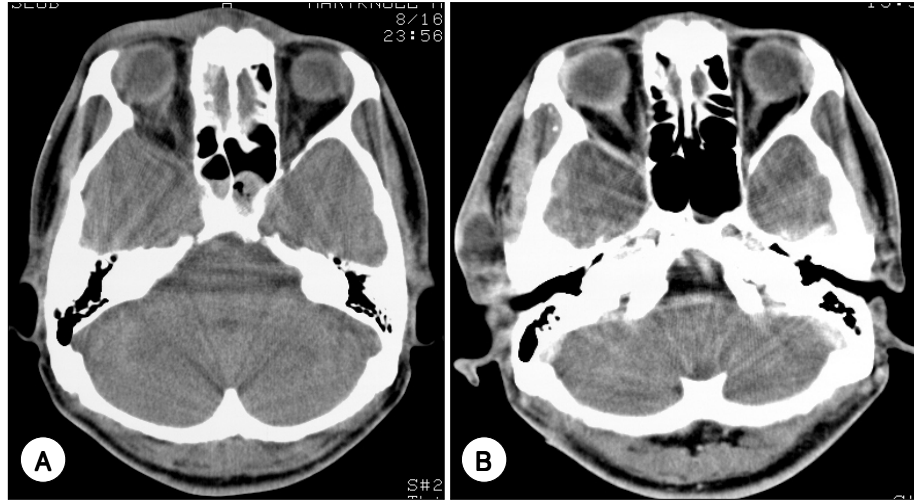
NF - 1 cafe - au - lait spot
 (Fig. 1), 가
 (Fig. 2A).
 0.3, 0.8 , Hertel
 13 mm, 13 mm 가
 ,
 가
 (Fig. 2B).
 ,
 (Figs. 3 and 4).
 7

20
 (frontotemporal approach)

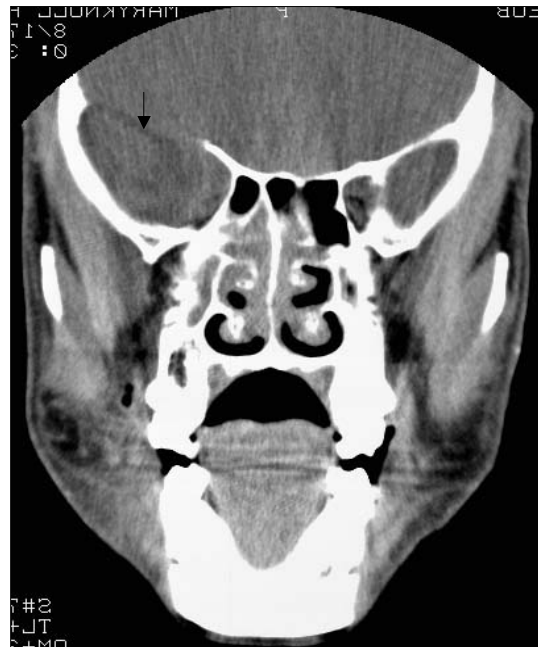

Fig. 3. Coronal CT scan showing the defect in lesser and greater wings of right sphenoid bone (arrow).

Fig. 4. Axial CT scan of right sphenoid dysplasia. After 10 days later from operation, right orbit was divided from right temporal lobe with surgicels and gelfoams. A : Preoperative view, B : Postoperative view.



surgicel gelfoam
(Fig. 4).

8가 , 가 1
 Recklinghausen . Recklinghausen
 cafe - au - lait spot,
 Lisch
 . Cafe - au - lait spot

3
0.5

고 찰

가

5 mm ,
 15 mm cafe - au - lait spot 6
 (freckling),

³⁾⁵⁾ 1929 Dandy⁴⁾

Lisch , 1 가

2가

NF - 1 1~7%

⁵⁾ NF - 1

⁷⁾ NF - 1

⁴⁾

7~10

가

6가

6

NF - 1

⁶⁾

⁵⁾

NF - 1 ⁵⁾⁶⁾

⁸⁾

NF - 1
 methyl methacrylate
 lastic reconstruction)¹⁰⁾
 (autogeneous reconstruction)
 .¹¹⁾ Papay ¹²⁾
 -
 6
 gelfoam
 surgicel
 중심 단어 : 1

ciput: Pathological considerations. *Semin Ultrasound CT MR* 1993;14:160-77.
 2) Harkens K, Dolan KD. *Correlative imaging of sphenoid dysplasia accompanying neurofibromatosis. Ann Otol Rhinol Laryngol* 1990;99:137-41.
 3) Binet EF, Kieffer SA, Martin SH, Perterson HO. *Orbital dysplasia in neurofibromatosis. Radiology* 1969;93:829-33.
 4) Dandy WE. *An operative treatment for certain cases of meningocele (or encephalocele) into the orbit. Arch Ophthalmol* 1929;2:123-32.
 5) Hunt JC, Pugh DG. *Skeletal lesions in neurofibromatosis. Radiology* 1976;76:1-19.
 6) Macfarlane R, Levin AV, Weksberg R, Blaser S, Rutka JT. *Absence of the greater sphenoid wing in neurofibromatosis type I: Congenital or acquired: case report. Neurosurgery* 1995;37:129-33.
 7) Jacquemin C, Mullaney P, Bosley TM. *Abnormal development of the lesser wing of the sphenoid with microphthalmos and microcephaly. Neuroradiology* 2001;43:178-82.
 8) Wiesenfeld D, James PL. *Pulsating exophthalmos associated with neurofibromatosis. J Maxillofac Surg* 1984;12:11-3.
 9) Snyder BJ, Hanieh A, Trott JA, David DJ. *Transcranial correction of orbital neurofibromatosis. Plast Reconstr Surg* 1998;102:633-42.
 10) Reinsen K, Lawson W, Biller HF. *Acryl frontal cranioplasty. Head Neck Surg* 1986;9:32-41.
 11) McDermott MW, Durity FA, Rootman J, Woodhust WB. *Usefulness of the orbitofrontomalar approach associated with bone reconstruction for frontotemporosphenoidal meningiomas. 1990;26:107-16.*
 12) Papay FA, Zins JE, Hahn JF. *Split calvarial bone graft in cranio-orbital sphenoidal wing reconstruction. J Craniofac Surg* 1996;7:133-9.

REFERENCES

1) Laine FJ, Kuta AJ. *Imaging the sphenoid bone and basioc-*