

설 암

연세대학교 의과대학 이비인후과학교실
최 은 창

Oral Tongue Cancer

Eun Chang Choi, MD

Department of Otorhinolaryngology, Yonsei University College of Medicine, Seoul, Korea

구강설암의 병리소견

전암병소(Premalignant lesions)	병리조직 소견	
(leukoplakia)	(patch)	87%
	가	(sarcoma),
	(lymphoma),	(melanoma)
	3가	(exophytic),
2 가	(ulcerative),	(infiltrative)
	가	가
		가
		가
(stripping)	가	1 cm
4% 가	가	가
(erythroplakia)	가	(plaque)
	가	(
: , 120 - 752	134	, verrucous carcinoma)
: (02) 361 - 8481	: (02) 393 - 0580	(tobacco
E - mail : eunchangmd@yumc.yonsei.ac.kr		

chewing)

(T),
가
Whitehurst 가 2 cm

(well differentiated),
(moderately differentiated), (poorly differentiated)
Broders

, Ho
DNA flow cytometry가

(moderate well differentiated) 가 4가
Broders
1 (grade) (pleomor- phism) (mitoses)
4 (grade)
(keratinization)가

DNA flow cytometry
Hemmer DNA flow cyto- metry (aneuploid cell)가
가
Jesse T 가
Spiro

1 2

T
2 mm 가, T2 3 mm 8 mm , T3
9 mm

임상특징

임상증상과 증후

가 2 mm

, , , ,
가 45% 가
가 33%

가 가 가
가
가 1.5 mm
가

가
(loose connective

tissue)

가

가

가

가 2 cm

가 2 mm

가

가

. Nathanson

임상예후에 영향을 주는 요인

가

가
1
가 10 mm
25%, 52% 10 mm 58%
87% 가
. Fakh
가 4 mm
가
가 4 mm 4 mm
가 4 mm 2
4 mm 8 12
가
2
경부전이
34% 50%
63
(Table 1)
44%
26.7%
50%가
가 가 가 가
T1 25% 가 T4
60% (Table 2).

Table 1. Pathologic T stage of oral tongue and Floor of mouth (63 SCC cases of Oral tongue and Mouth floor in Severance hospital from 1992 to 2001. Korean J Otolaryngol 2002 ; 45 : 154-8)

	No. of cases		
	Floor of mouth	Oral tongue	Total
T1	4	12	16
T2	6	25	31
T3	3	8	11
T4	2	3	5
Total	15	48	63

Table 2. Incidence of nodal metastasis by primary subsites and T stages

	No. of cases	No. of Pn+	%
Primary sites			
Floor of mouth	15	4	26.7
Oral tongue	48	24	50
T stage			
T1	16	4	25
T2	32	14	43.8
T3	10	5	50
T4	5	3	60

가
가
가 Teichgraeber 49
17 35%
42 12 37%
. Shah 501
34%
31%, 26%
43
12 27.9%
(Table 3).
15% 20%
가
Kligerman T1 T2

Table 3. Clinical and pathological nodal staging of squamous cell carcinoma in floor of mouth and oral tongue

pN stage	No. of Cases		
	cN0 (n=43)	cN+ (n=20)	Total (%)
pN0	31	4	35 (55.6)
pN+	12	16	28 (44.4)
N1	6	3	9 (14.3)
N2a	0	2	2 (3.2)
N2b	6	9	15 (23.8)
N2c	0	2	2 (3.2)
N3	-	-	-

N0 neck (43 cases) - SOND : 36 cases, MRND : 7 cases
 N+ neck (20 cases) - SOND : 3 cases, RND : 12 cases, extended RND : 2 cases, MRND : 3 cases
 *SOND : supraomohyoid neck dissection, RND : radical neck dissection, MRND : modified radical neck dissection.

Table 4. Prevalence of ipsilateral nodal metastasis by neck level

No. of Cases (%)	No. of cases (%)	
	Elective ND (n=43)	Therapeutic ND (n=20)
I	4 (9.3)	7 (35)
II	7 (16.3)	7 (35)
III	4 (9.3)	6 (30)
IV	0*	3 (17.6)
V	0*	2 (11.8)

Elective ND (43 cases) - SOND : 36 cases, MRND : 7 cases, Therapeutic ND (20 cases) - SOND : 3 cases, RND : 12 cases, extended RND : 2 cases, MRND : 3 cases.
 SOND : supraomohyoid neck dissection, RND : radical neck dissection, MRND : modified radical neck dissection, ND : neck dissection. * : data from 7 cases underwent type III MRND(modified radical neck dissection) : 17.6% (3/17), : 11.8% (2/17)

67
 13%, 35%
 21%
 3.5
 72%
 49%
 가 4 mm
 cN0
 level
 가 . Shah 21 cN0
 192 (radical neck dissection)
 level , , ,
 19%, 16%, 14%, 3%
 level V 가 level
 , , ,
 level 가
 16%, 12%, 7%, 2%
 (supraomohyoid neck dissection)
 Shah

가
 43 36
 7 level V
 level
 cN0 7 level V
 가 level V
 (Table 4).
 level
 , ,
 cN+ 20 level 7
 (35%), level 7 (35%), level 6 (30%), level
 3 (15%), level V 2 (10%) , , , , V
 Shah
 (Table 4).
 level V 가
 level 가
 가 Shah
 cN+ level V
 12% 20% 가
 cN2

가 , (Table 5).

Teichgraeber, Decroix, Shah T2 가 41% 가 T1 32%, T3 14%, T4 13% (Table 6).

가

가

13 24 37

1 40%

36 36 N0 N1 가 가 82 (46.9%)

1 가 2.8% 가 N2가 22%

가 N1 21%, N3가 4% 8 (4.5%) (Table 7).

가

Decroix level 10%, level 22%, level 18%, 5% Shah level , ,

(randomized) 가

구강설암의 치료

원발병소 및 경부 치료

가

가

가

가

1997 AJCC(American Joint Committee on Cancer)

1 가 23%, 2 가 22%, 3 가 21%, 4 가 34% 1,

2 3, 4

Teichgraeber, Decroix, Shah T2 가 41% 가 T1 32%, T3 14%, T4 13% (Table 6).

Decroix N0 N1 가 가 82 (46.9%) 가 N2가 22% N1 21%, N3가 4% 8 (4.5%) (Table 7).

Decroix level 10%, level 22%, level 18%, 5% Shah level , ,

Table 5. Patient distribution by stage (oral tongue SCC 175 cases in Severance hosp, from 1976 to 2001)

Stage	No. of patients (%)
I	41 (23)
II	39 (22)
III	37 (21)
IV	58 (34)
Total	175 (100)

Table 6. Tumor and node stage

	T1	T2	T3	T4	Total (%)
N0	41	39	7	6	93 (53)
N1	6	15	9	6	36 (21)
N2	6	17	7	8	38 (22)
N3	2	1	2	3	8 (4)
Total (%)	55 (32)	72 (41)	25 (14)	23 (13)	175 (100)

Table 7. Nodal presentation

	Ipsilateral	Contralateral
I	30	6
II	38	2
III	12	-
IV	-	-
V	2	-

Total cases of positive node : 42/90 (46.7%)

:
 level
 가 50% level
 가 level V
 가 level 가
 (supraomohyoid neck dissection) , 가 Bradfield
 (anterolateral neck dis-
 section)
 가
 level
 1940 1950 가
 가
 가
 가
 가 Spiro T2
 T1 1974 가
 Whitehurst T2 1977
 가 son T2 1980 John-
 . 1970 가 field 가 1983 Brad-
 가 2 cm
 , 1984 Teichgraeber T2
 가 T1
 3 29.1%, 42.9%, 77.0% 38.4% 25% 45% 가
 23% 66%
 가
 가 20% 50% 가
 가
 가 가
 가 Ho 1, 2
 40% 가
 30%
 가
 가 86% 1, 2

가
 가 Ho 가
 가 가
 20% 가 30% 5 가 가
 Spiro
 40%
 3
 Cunningham NO
 가 (modified neck
 dissection) T2 가 NO Mendelhall Million
 가 Million 1970 가
 95% 가 1
 가 2 , T2N0M0 . 3
 4 가
 가
 가 2 가 , 1,
 3, 4
 가 1, 2 3, 4
 가 4500 5000 rad (Table 8).
 Leipzig 1 2
 3 가
 Jesse
 가 2
 4% 가
 가
 가
 가

Table 8. Treatment modality

Stage	Surgery	Radiation	Combined	Total
I	23	10	8	41 (23)
II	13	12	14	39 (22)
III	7	17	13	37 (21)
IV	10	30	18	58 (34)
Total	53 (30)	69 (40)	53 (30)	175 (100)

3 4 가 Mulholland Razack

가 (Table 9).

가 Leipzig

가 2 mm NO 3, 4

3 76%, 61% 30% 31%

Leipzig 3 78.4% 59%

58.5%, 84.6%

(Table 9).

T1 7.3%

Kajanti 9.8%, T2가 3.8% 14.3%, T3가 21.4%

2 1 4 30%

76%, 71%, 45%, 0% 48%

T1 15.9% 35.7%, T2가 19.2% 42.9%, T3가 28.5% 42.9%

1, 2 76.9% 47.3% 9%

가

Leipzig 92% 30%

(Table 9).

. Zele-

fsky

Table 9. Local control rate (F/U : 123 cases)

Stage	Surgery	Radiation	Combined	Total
I	15/18	4/ 9	4/ 7	23/34 (68)
II	5/ 8	5/10	7/12	17/30 (59)
III	2/ 3	4/13	7/12	13/28 (42)
IV	3/ 4	6/26	10/15	19/45 (46)
Total	25/33 (76)	19/58 (30)	28/46 (61)	72/137 (53)

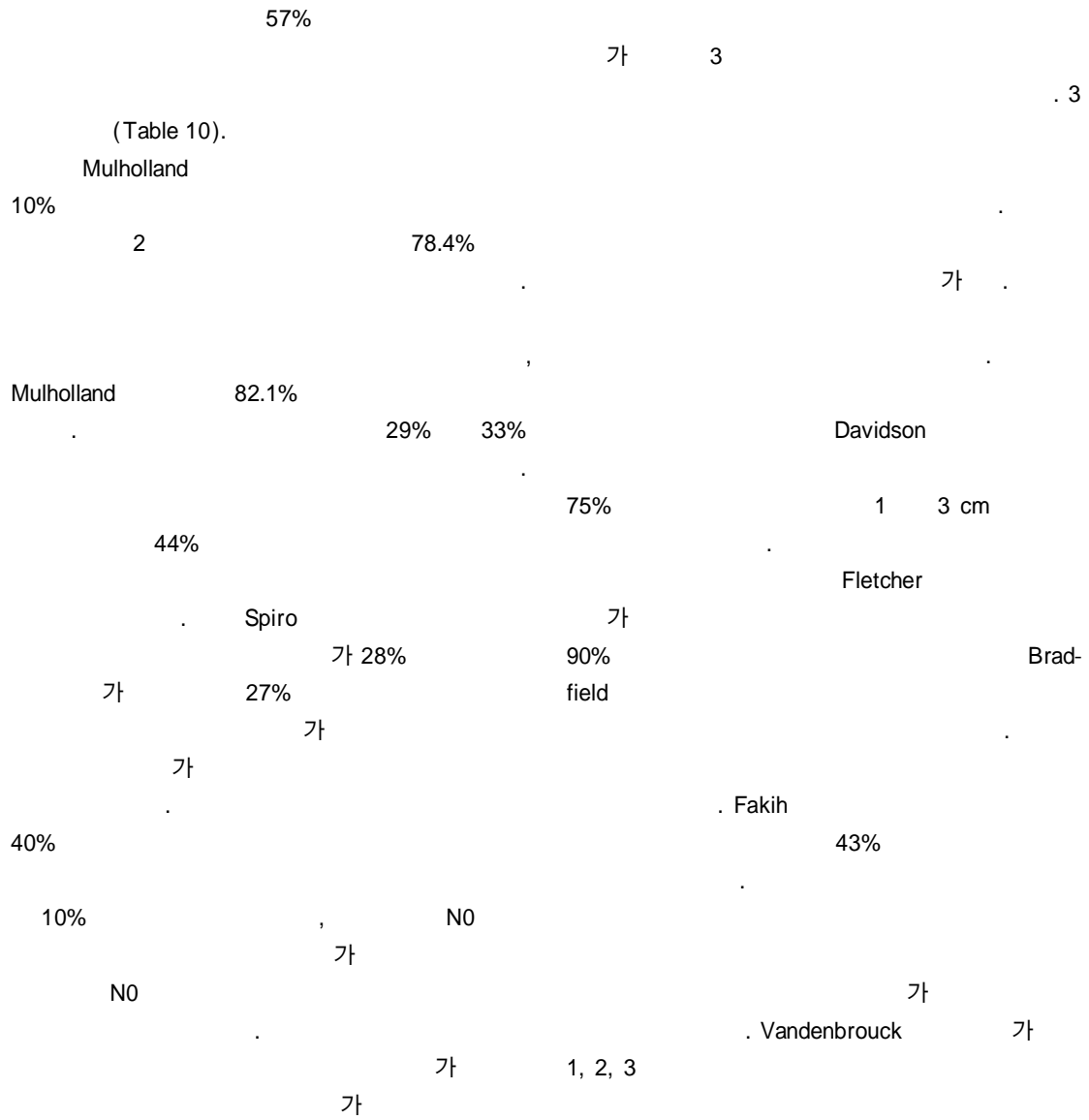


Table 10. Patterns of failure (%)

Failure site	Surgery	Radiation	Combined
Local	0 (0)	24 (35)	11 (21)
Regional	3 (5)	6 (9)	10 (19)
Locoregional	2 (4)	9 (13)	2 (4)
Distant mets	0 (0)	1 (1)	1 (2)
None	45 (84)	11 (16)	23 (42)
Unknown	1 (2)	18 (26)	6 (12)
Total(%)	53 (100)	69 (100)	53 (100)

:
 가 Shah 가 가
 가 192 level , , 가 가
 1.5%
 수술적 접근방법 및 절제술 . Pull through 가 가 . Pull through
 가 가 가 가 pull through
 가 가 가 가 가 .
 가 가 가 가 pull through
 가 가 가 (mental
 , nerve)
 가 .
 2 cm
 pull through (lingual release) (visor flap) 2 cm
 approach)
 가 . Kamata T3
 1.5 cm 1 cm
 pull through T2 T3 Kano T1 1 cm, 2 cm
 1 cm,
 2 cm
 가 pull through 5 mm
 5 가 가

가 fibular
가 가
Conley
가 Robbins
가 palatal augmentation prosthesis
(Table 12)
가 가
가 Conley 가
new tongue
Salibian
가 (sulcus)가 (cricopharyngeal my-
otomy) 가
groin osteocutaneous flap (condyle)
가 NO
1 (comprehensive neck dissection)
pull - through
double 가

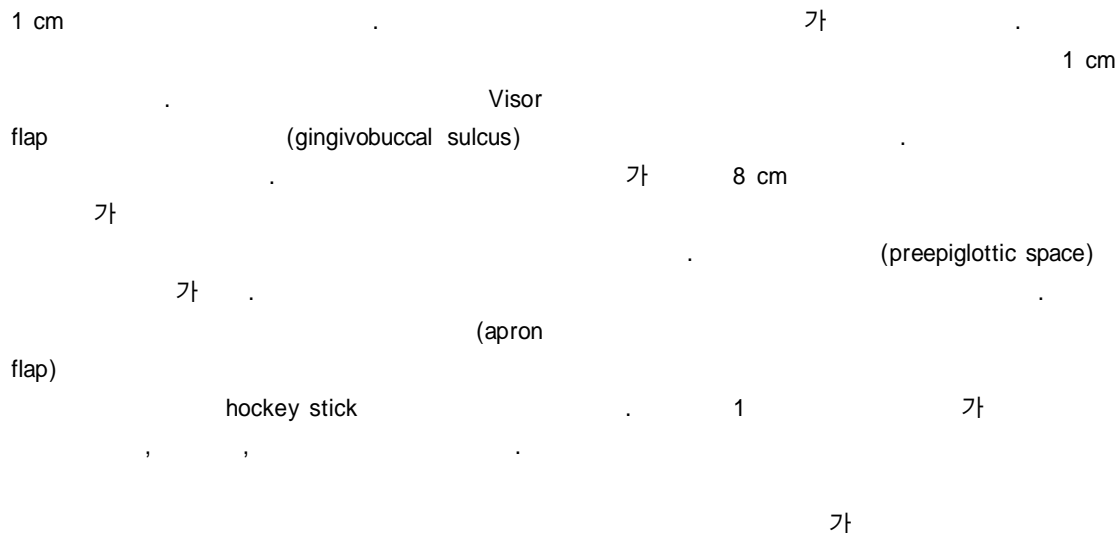


Table 11. Five-year survival rate by surgical method (%)

Surgery	Stage I & II	Stage III & IV
Glossectomy	13/20 (65.0)	2/ 4 (50.0)
G+ND	10/12 (83.3)	8/18 (44.5)
Margin		
>2 cm	12/17 (70.6)	3/ 7 (42.9)
<2 cm	11/15 (73.4)	7/15 (46.7)

('76 - '97 : 54 cases)

(Table 12).

예 후

가

Table 12. Summary of total glossectomy cases (extracted from Korean J Otolaryngol 39 : 3 ; 1996)

Case	1	2	3	4	5
Age/Sex	48/M	49/F	50/M	53/M	41/M
Primary site	FOM	Oral tongue	Oral tongue	Supraglottic	Oral tongue
Stage	rT4N0M0	pT4N2CM0	pT4N1M0	pT4N2cN0	pT4N0M0
Approach	Partial mn Visor	Segmental mn Lip split	Pull through	Pull through Apron	Segmental mn Lip split
Operation	T/G, BND	T/G, BND	T/G, BND	T/G, T/L,BND	T/G,RND
Reconstruction					
Mandible	None	AO plate	None	None	Fibular flap
Tongue	PMMF	PMMF	PMMF	PMMF	Fibular flap
Complication	None	None	None	Fistula	None
Oral feeding start	POD 17	POD 14	POD 30	POD 60	POD 26
Tolerable diet	Liquid	Liquid	Semisolid	Soft	Soft
Follow up (months)	DOD 15/12	DOD 17/12	DOD 8/12	NED 8/12	NED 7/12
Cause of death	Primary failure	Primary failure	Primary & bone		
Comment	XRT failure	Postop XRT	Postop XRT		Postop XRT

mn : mandibulectomy, T/G : total glossectomy, T/L : total laryngectomy, RND : radical neck dissection, BND : bilateral neck dissection, PMMF : pectoralis major myocutaneous flap, POD : postoperative day, DOD : died of disease, NED : no evidence of disease, XRT : radiotherapy.

가 가
 barrier) (anatomical
 가 65%,
 가 83%
 가
 Spiro 5 42%
 1 68%, 4 14% 가 1
 Bradfield
 5 78.7%, 2 cm 2 cm
 20.7% 58.5% 70.6% 73%
 Lam 50.6%, Spiro 62.1%
 Decroix 48% 가
 (Table 11).

중심 단어 :

REFERENCES

Spaulding T1 31%, T2 44%, T3
 56%, T4 100% N
 N1 N2
 가
 가
 가
 가
 Bradfield
 5
 1 58% 75%,
 2 66% 71%
 5 1 64%, 2
 31% Razack
 가

- 1) Choi EC, Kim SS, Park NS, Hong WP. *Mandibular osteotomy in the surgical approach to the oral cavity and oropharyngeal cancer. Korean J Otolaryngol* 1994;37:1274-8.
- 2) Choi EC, Hong WP. *Partial mandibulectomy for oral cavity and oropharyngeal carcinoma. Korean J Head Neck Oncol* 1994;10:163-70.
- 3) Choi EC, Kim ES, Lee JJ, Kim KM, Hong WP. *Therapeutic Analysis of Squamous Cell Carcinoma of the Oral Tongue. Korean J Otolaryngol* 1995;38:413-23.
- 4) Choi EC, Kim ES, Lee HB, Choi HS. *Reconstruction after total glossectomy. Korean J Otolaryngol* 1996;39:500-7.
- 5) Choi EC, Choi YS, Kim DY. *Surgical approach to the oral cavity and oropharyngeal cancer: Visor flap approach. Korean J Head Neck Oncol* 1999;15:226-31.
- 6) Choi EC, Choi JY, Kang SS. *True island pectoralis major myocutaneous flap: its advantages. Korean J Otolaryngol* 2000;43:201-7.
- 7) Choi EC, Koh YW, Lee YH, Park HJ, Lee KH. *Surgical approach to the oral cavity: Techniques, advantages and disadvantages of pull through approach. Korean J Otolaryngol* 2001;44:89-95.
- 8) Kim CH, Bae JH, Shin SH, Koh YW, Kim YH, Choi EC. *Cervical Lymph Node Metastasis of Squamous Cell Carcinoma of the Oral Tongue and Floor of Mouth. Korean J Otolaryngol* 2002;45:154-8.
- 9) Brown B, et al. *Prognostic factors in mobile tongue and floor of mouth carcinoma. Cancer* 1989;64:1195-202.
- 10) Cummings CW, et al. *Otolaryngology Head and Neck Surgery. 2nd Ed. St. Louis, Mosby Year Book;1993. p.1277-9.*
- 11) Cunningham MJ, et al. *Cervical lymph node metastasis after local excision of early squamous cell carcinoma of the oral cavity. Am J Surg* 1986;152:361-6.

- 12) Davidson TM, et al. *The biology of head and neck cancer; Detection and control by parallel histologic sections.* Arch Otolaryngol 1984;110:193-6.
- 13) Decroix Y, Ghossein N. *Experience of the Curie Institute in treatment of cancer of the mobile tongue, I. Treatment policies and results.* Cancer 1981;47:496-502.
- 14) Decroix Y, Ghossein N. *Experience of the Curie Institute in treatment of cancer of the mobile tongue, II. Management of the neck nodes.* Cancer 1981;47:503-8.
- 15) Fakih AR, et al. *Elective Versus therapeutic neck dissection in early carcinoma of the oral tongue.* Am J Surg 1989;158:309-13.
- 16) Farrar W, et al. *Follow-up on flow cytometric DNA analysis on squamous cell carcinoma of the tongue.* Am J Surg 1989;157:377-80.
- 17) Fletcher GH. *Elective irradiation of subclinical disease in cancers of the head and neck.* Cancer 1972;29:1450-4
- 18) Hemmer J, et al. *Prognostic implications of DNA ploidy in squamous cell carcinomas of the tongue assessed by flow cytometry.* Cancer Res Clin Oncol 1990;116:83-6.
- 19) Ho CM, et al. *Occult lymph node metastasis in small oral tongue cancers.* Head & Neck;1992. p.359-63.
- 20) Ildstad ST, et al. *Squamous cell carcinoma of the tongue: A comparison of the anterior two thirds of the tongue with its base.* Am J Surg 1983;146:456-61.
- 21) Jesse, et al. *Cancer of the oral cavity. Is elective neck dissection beneficial ?* Am J Surg 1970;120:505-8.
- 22) Johnson MJT, et al. *Management of T1 carcinoma of the anterior aspect of the tongue.* Arch Otolaryngol 1980;106:249-51.
- 23) Jones JB, et al. *Carinoma of the tongue in young patients.* J Otolaryngol 1989;18:105-8.
- 24) Bocca E, Pignataro O, Oldini C, Cappa C. *Functional neck dissection: An evaluation of review of 843 cases.* Laryngoscope 1984;94:942-5.
- 25) Lam KH, et al. *Surgical treatment of cervical lymph nodes in carcinoma of the tongue.* Aust NZJ Surg 1980;50:37-41.
- 26) Lee JG, Litton VB. *Occult regional metastasis: Carcinoma of the oral tongue.* Laryngoscope;1972. p.1273-81.
- 27) Leipzig B, et al. *Carcinoma of the anterior tongue.* Ann Otol 1982;91:94-7.
- 28) Lydiatt DD, et al. *Treatment of stage I and II oral tongue cancer.* Head & Neck;1993. p.308-12.
- 29) Marks JE, et al. *Carcinoma of the oral tongue: A study of patient selection and treatment results.* Laryngoscope 1981; 91:1548-59.
- 30) Mashberg A, et al. *Appearance, site of occurrence, and physical and clinical characteristics of oral carcinoma in Torino, Italy.* Cancer 1989;63:2522-7.
- 31) Mendenhall WM, et al. *T2 oral tongue carcinoma treated with radiotherapy: analysis of local control and complication.* Radio Oncol 1989;16:275-81.
- 32) Million RR. *Elective neck irradiation for TxNo squamous carcinoma of the oral tongue and floor of mouth.* Cancer 1974;34:149-55.
- 33) Mohit-Tabatabai MA, et al. *Relation of thickness of floor of mouth Stage I and II cancers to regional metastasis.* Am J Surg 1986;152:351-3.
- 34) Mulholland MW, et al. *Aggressive surgical therapy after irradiation failure in treatment of cancer of the oral tongue* Arch Surg 1984;119:394-9.
- 35) Nathanson A, et al. *Evaluation of some prognostic factors in small squamous cell carcinoma of the mobile tongue: A multicenter study in Sweden.* Head & Neck;1989. p.387-92.
- 36) Orregia, et al. *Risk factors for cancer of the tongue in Uruguay.* Cancer 1991;67:180-3.
- 37) Razack MS, et al. *The role of initial modality in treatment of squamous cell carcinoma of the tongue.* J Surg Oncol 1982;19:136-8.
- 38) Shah, et al. *The patterns of cervical lymph node metastases from squamous carcinoma of the oral cavity.* Cancer 1990; 66:109-13.
- 39) Spaulding CA, et al. *The influence of extent of neck treatment upon control of cervical lymphadenopathy in cancers of the oral tongue.* Int J Radiol Oncol Biol Phys 1991;21: 577-81.
- 40) Spiro RH, et al. *predictive value of tumor thickness in squamous carcinoma confined to the tongue and floor of mouth.* Am J Surg 1986;152:345-50.
- 41) Umeda M, Satoshi Y, Yoshiaki T, Akiteru O, Koichi N, Keikichi S. *Lymph node metastasis in squamous cell carcinoma of the oral cavity: correlation between histologic features and the prevalence of metastasis.* Head Neck 1992; 14:263-72.
- 42) Kligerman J, Lima RA, Soares JR, Prado L, Dias FL, Freitas EQ, et al. *Supraomohyoid neck dissection in the treatment of T1/T2 squamous cell carcinoma of oral cavity.* Am J Surg 1994;168:391-4
- 43) Spiro RH, et al. *Surgical approach to squamous carcinoma confined to the tongue and the floor of the mouth.* Head & Neck;1986. p.27-36.
- 44) Takagi M, et al. *Causes of oral tongue cancer treatment failures. Analysis of autopsy cases.* Cancer 1992;69:1081-7.
- 45) Teichgraeber JF, Clairmont AA. *The incidence of occult metastases for cancer of the oral tongue and floor of the mouth: Treatment rationale.* Head & Neck;1984. p.15-21.
- 46) Vandenbrouck C, et al. *Elective versus therapeutic radical neck dissection in epidermoid carcinoma of the oral cavity. Results of a randomized clinical trial.* Cancer 1980;46:386-90.
- 47) White D, Byers RM. *What is the preferred initial method of treatment for squamous carcinoma of the tongue ?* Am J Surg 1980;140:553-5.
- 48) Whitehurst JO, Droulias CA. *Surgical treatment of squamous cell carcinoma of the oral tongue. Factors influencing survival.* Arch Otolaryngol 1977;103:212-5.
- 49) Zelefsky B. *Postoperative radiation therapy for squamous cell carcinomas of the oral cavity and oropharynx: impact of therapy on patients with positive surgical margins.* Int J Radiol Oncol Biol Phys 1993;25:17-21.
- 50) Biller HF, Lawson W, Back SM. *Total glossectomy: A technique of reconstruction eliminating laryngectomy.* Arch Otolaryngol 1983;109:69-73.
- 51) Conley J, Sachs ME, Parke RB. *The new tongue.* Otolaryngol Head Neck Surg 1982;90:58-68.
- 52) Fletcher GH, Evers WJ. *Radiotherapeutic management of*

- surgical recurrences and postoperative residuals in tumors of the head and neck. *Radiology* 1970;95:185-8.
- 53) Gehanno P, Guedon C, Barry B, et al. *Advanced carcinoma of the tongue: total glossectomy without total laryngectomy. Review of 80 cases. Laryngoscope* 1992;102:1369-71.
 - 54) Harrison D. *The questionable value of total glossectomy. Head Neck Surg* 1983;6:632-8.
 - 55) Hidalgo D. *Fibular free flap: A new method of mandible reconstruction. Plast Reconstr Surg* 1989;84:71-8.
 - 56) Keyserlingk JR, Francesco J, Breach N, et al. *Recent experience with reconstructive surgery following major glossectomy. Arch Otolaryngol Head Neck Surg* 1989;115:331-8.
 - 57) Krepsi YP, Sisson GA. *Reconstruction after total or subtotal glossectomy. Am J Surg* 1983;146:488-92.
 - 58) Looser KG, Shah JP, Strong EW. *The significance of positive margins in surgically resected epidermoid carcinomas. Head Neck Surg* 1978;1:107-11.
 - 59) Razacj MS, Sako K, Bakamjian VY, et al. *Total glossectomy. Am J Surg* 1983;146:509-11.
 - 60) Robbins KT, Bowman JB, Jacob RF. *Postglossectomy deglutitory and articulatory rehabilitation with palatal augmentation prosthesis. Arch Otolaryngol Head Neck Surg* 1987;113:1214-8.
 - 61) Robertson MS, Robinson JM, Horsfall RM. *A technique of tongue reconstruction following near total glossectomy. J Laryngol Otol* 1987;101:260-5
 - 62) Rodriguez R, Pery C, Soo KC, et al. *Total glossectomy. Am J Surg* 1987;154:415-8.
 - 63) Salibian AH, Allison GR, Rappaport I, et al. *Total and subtotal glossectomy: function after microvascular reconstruction. Plast Reconstr Surg* 1990;85:513-24.
 - 64) Schleuning AJ, Summers CW. *Carcinomas of the tongue: review of 220 cases. Laryngoscope* 1972;82:1146-454.
 - 65) Skolnick EM, Saberman MN. *Cancer of the tongue. Otolaryngol Clin North Am* 1972;2:603-15.
 - 66) Tiwari R, Karim ABM, Greven AJ, et al. *Total glossectomy with laryngeal preservation. Arch Otolaryngol Head Neck Surg* 1993;119:945-9.
 - 67) Weber RS, Ohlms L, Bowman J, et al. *Functional results after total or near total glossectomy with laryngeal preservation. Arch Otolaryngol Head Neck Surg* 1991;117:512-5.
 - 68) Hollinshed WH. *Anatomy for Surgeons: The Head and Neck. 3rd ed. Harper & Row; 1982. p.291-384.*
 - 69) Kim SY. *Malignant neoplasm of oral cavity and oropharynx In: Kim JS et al. Otolaryngology-Head and Neck Surgery Ijogak;2002. p.1334-52.*
 - 70) Korean Society of Head and Neck Surgeons. *Head and Neck Surgery Hankook Medical Publishing Co;2000. p.291-311.*