

비인강에 발생한 신경초종 1례

전주예수병원 이비인후과

전진호 · 정찬일 · 이진 · 이시영

A Case of Neurilemmoma of the Nasopharynx

Jin Ho Jeon, MD, Chan Il Jung, MD, Jin Lee, MD and See Young Lee, MD

Department of Otolaryngology, Presbyterian Medical Center, Jeonju, Korea

-ABSTRACT-

Neurilemmoma is a benign tumor which arises from the nerve sheath of sympathetic, peripheral, and cranial nerves except optic and olfactory nerves. Approximately 25% to 45% of neurilemmoma occur in the head and neck. The most common site is the parapharyngeal space of the neck, nasopharyngeal occurrence is extremely rare. Recently, we have experienced a case of neurilemmoma originated from the nasopharynx in a 20-year-old man. Now we report the case with brief literature review. (J Clinical Otolaryngol 2003;14:151-154)

KEY WORDS : Neurilemmoma · Nasopharynx.

서론

Schwann

증례

20

2

2002

가

9 23

가

25~45%

¹⁾²⁾

가

가

³⁾

(posterior pillar)

가

2 cm

, 가

⁴⁾

(salpingo-

1

pharyngeal fold)

(Fig. 1).

: 2003 4 1

: 2003 5 6

: , 560 - 750

17가 300

: (063) 230 - 8155 · : (063) 230 - 8463

E - mail : kbrain93@hanmail.net

(Fig. 2).

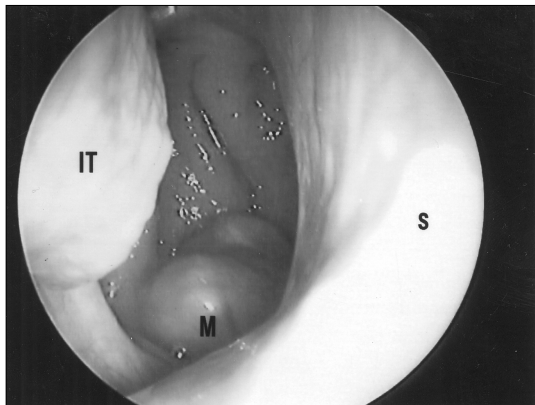


Fig. 1. Endoscopic finding of right nasal cavity. Photograph shows yellow mass originated from right nasopharyngeal wall (IT : inferior turbinate, M : mass, S : septum).

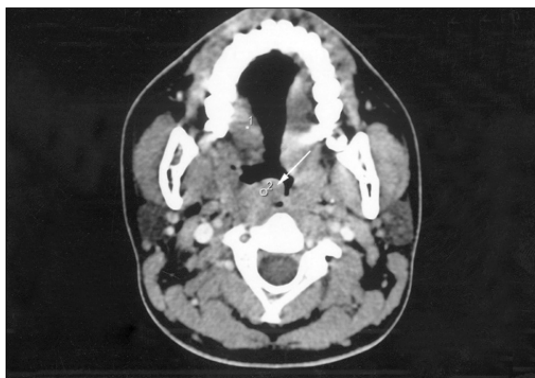

Fig. 2. Preoperative axial CT scan at low maxilla level. About 2 x 2 cm sized mass (white arrow) is seen at post-rolateral aspect of right nasopharyngeal lumen.

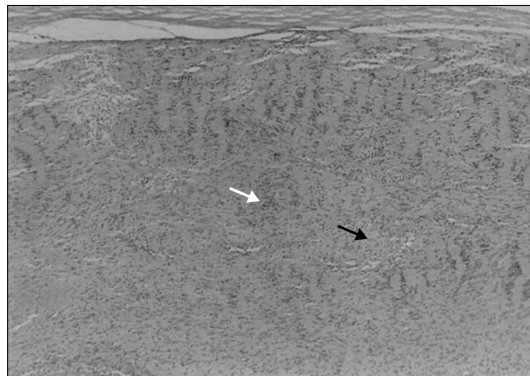


Fig. 3. Microphotograph of mass shows characteristic pattern of alternating Antoni A and Antoni B. Antoni A (white arrow) is characterized by compact Schwann cells with nuclear palisading, whereas Antoni B (black arrow) exhibits a degree of cell pleomorphism in a loosely arranged reticulum network (H & E, x 40).

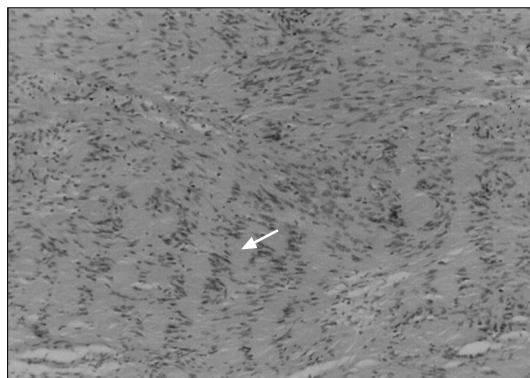

Fig. 4. Antoni A areas illustrating nuclear palisading with formation of the Verocay bodies (white arrow) (H & E, x 250).

가
 Rose
 2 cm
 4 cm 가 가
 2.2 x 2 x 1.7 cm

가
 Antoni A
 Antoni B
 (Fig. 3).
 Verocay body
 (Fig. 4).
 고 찰
 1910 Verocay neurinoma

3

Schwannoma⁵⁾ Neurilemmoma¹⁴⁾ Antoni A Antoni B

6 : 4

6) , Anderson⁷⁾ 2~

가

20 30 가

9)

가

26.9 ,⁸⁾

가

가 2)

가 15)

11)

가 13)

가

가 12)

가 1)

중심 단어 :

REFERENCES

- 1) Seo YL, Nam SY, An KH, Kim SY, Lee KS. *External nerve sheath tumors of the head and neck. Korean J Otolaryngol 1997;40:908-13.*
- 2) Kim MS, Kim YH, Jung HJ, Hong WP. *A case of neurilemmoma of the posterior wall of the hypopharynx. Korean J Otolaryngol 1998;41:274-7.*
- 3) Lall GS, Walsh RM, Rowlands DC, Donaldson I. *Schwannoma (neurilemmoma) of the tonsil. J Laryngol Otol 1999; 113:585-6.*
- 4) Schwartz TH, Bruce JN. *Extended frontal approach with bilateral orbitofrontoethmoidal osteotomies for removal of a giant extracranial schwannoma in the nasopharynx, sphenoid sinus, and parapharyngeal space. Surg Neurol 2001; 55:270-4.*
- 5) Kim YH, Yoon JS, Choi EC, Kim ES. *A case of neurilemmoma of the larynx. Korean J Otolaryngol 1995;38:2082-7.*
- 6) Futney FJ. *Neurogenic tumor of head and neck. Laryngoscope 1964;74:1037-59.*
- 7) Anderson WAD, Kissane JM. *Pathology, 6th Ed. Saint Louis; Mosby Company;1977. p.1843-4.*
- 8) Gordon BN, Kenneth DD. *Neurogenic tumors of nose and throat. Arch Otolaryngol 1947;46:163-79.*
- 9) Gallo WJ, Moss M, Shapio DN, Gaul JV, Mich HW. *Neurilemmoma: Review of the literature and report of five cases. J Oral Surg 1977;35:235-6.*
- 10) Gore DO, Rankow R, Hanford JM. *Parapharyngeal neurilemmoma. Surg Gyn Obst 1956;103:193-201.*
- 11) Eom JW, Hwang BH, Kim TS. *A case of schwannoma of the hard palate. J Clinical Otolaryngol 2001;12:122-4.*

가 가 가

13)

Antoni A Antoni B An-

toni A (palisading)

Verocay body . Antoni B

가

J Clinical Otolaryngol 2003;14: 151-154

- 12) Dykstra PC. *The pathology of acoustic neuromas. Arch Otolaryngol 1964;80:605-16.*
- 13) Kim TH, Kim SJ, Cho SB, Kim JH. *A case of laryngeal schwannoma. J Clinical Otolaryngol 2002;13:140-3.*
- 14) Kim YK, Chung KH, Yoon YJ. *Two cases of neurilemmoma of the external auditory canal. Korean J Otolaryngol 1996; 8:469-72.*
- 15) Kragh LV, Soule EH, Masson JK. *Benign and malignant neurilemmomas of the head and neck. Surg Gyn Obst 1960;111: 211-8*