

하인두 금속성 이물의 이동에 의한 후인두 농양

원광대학교 의과대학 이비인후과교실,¹ 방사선학과교실²
이재훈¹ · 박수엽¹ · 최시성²

Retropharyngeal Abscess due to Migration of
Hypopharyngeal Metallic Foreign Body

Jae Hoon Lee, MD¹, Su Yeob Park, MD¹ and See Sung Choi, MD²

¹Department of Otolaryngology, ²Radiology, College of medicine, Wonkwang University, Iksan, Korea

-ABSTRACT -

Only a small number of ingested foreign bodies perforate the food passage and even a smaller fraction migrate extraluminally. Migrated foreign bodies have the potential to cause morbidity and mortality. This report describes a 59-year-old female patient who developed neck abscess due to perforation and extraluminal migration of a hypopharyngeal metallic foreign body. The abscess was successfully removed by CT guided aspiration and the patient was discharged without any specific complication. (J Clinical Otolaryngol 2002;13:234-237)

KEY WORDS : Migration · Hypopharyngeal metallic foreign body · CT guided aspiration

서 론

가

증 례

59

가

(migration)

8

(pyriform sinus)

2

: 2002 7 12

: 2002 8 23

: , 570 - 711

344 - 2

: (063)850 - 1310 · : (063)841 - 6556

E - mail : coolnose@wonkms.wonkwang.ac.kr

X - (Fig. 1)

8 가

(Fig. 2).

(abscess cavity)

(Fig. 3).

Amoxicillin with clavulanic acid
Metronidazole

5 cc

(Fig. 4).

1 38.5

2

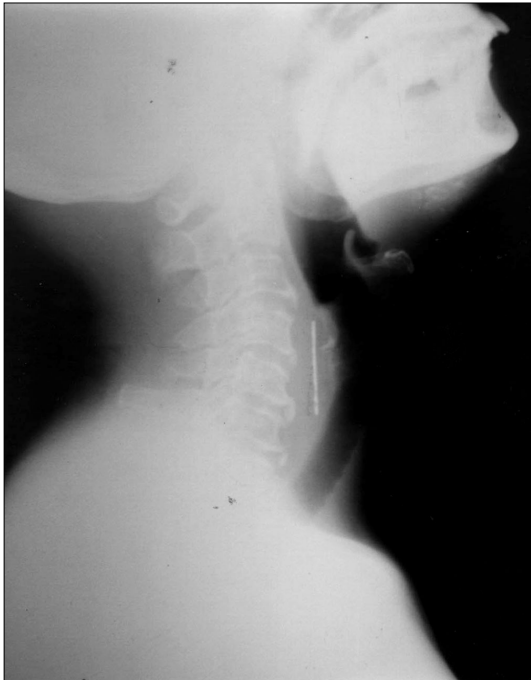

Fig. 1. Lateral view neck shows metallic foreign body.




Fig. 2. Sharp metallic foreign body(size 35 mm).

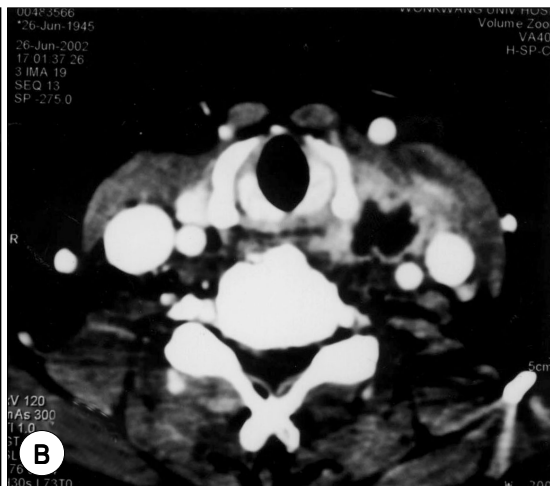
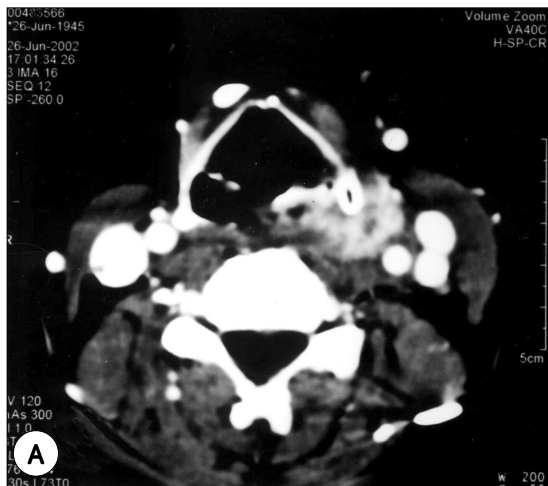

Fig. 3. A : CT scan shows inflammatory mass is around left pyriform sinus and retropharyngeal space. B : CT(inferior scan to A) scan shows abscess cavity with irregular marginated wall in retropharyngeal space.

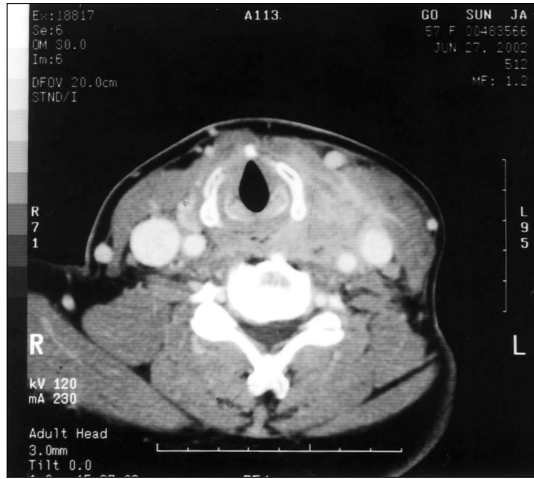

Fig. 4. CT scan after CT gruided aspiration shows abscess cavity is not seen but soft tissue swelling.

mina)
 Osinubi ⁵⁾
 , Feldhusen ⁶⁾
 (parapharyngeal abscess)
 가
 .
 .
 x -
 가 가
 가
 9 가
 3
 7
 (abscess cavity)
 2
 고 찰
 , , ,
 가 .¹⁾
 , X -
 Erez ²⁾
 , Muhanna ³⁾
 , Murthy ⁴⁾
 (pyriform sinus) (thyroid la-
 (Klebsiella)
 (Klebsiella)
 lactamase
 with clavulanic acid
 Metronidazole
 Penicillin
 amoxycillin
 , Herzon⁷⁾

(Ca-theter)

. Simon 8)

중심 단어 :

Scott 9)

가 24 48

가

REFERENCES

- 1) Shim WY, Jeong WH, Park JB, Kim CA, Baik SK. *Two Cases of Fish Bone Foreign Body Presenting as Tongue and Neck Mass. Korean J Otolaryngol* 2001;44:556-9.
- 2) Erez B, Zeev H, Zahava H, Meir F, Jona K. *Migration of fishbone following penetration of the cervical esophagus presenting as a thyroid mass. Auris Nasus Larynx* 1992;19:193-7.
- 3) Muhanna AA, Abu CKA, Dashti H. *Thyroid lobectomy for removal of a fish bone. J Laryngol Otol* 1990;104:511-2.
- 4) Murthy PS, Bipin TV, Ranjit R, Murty KD, George V, Mathew KJ. *Extraluminal migration of swallowed foreign body into the neck. Am J Otolaryngol* 1995;16:213-5.
- 5) Osinubi OA, Osiname AI, Lonsdale RJ, Butcher C. *Foreign body in the throat migrating through the common carotid artery. J Laryngol Otol* 1996;110:793-5.
- 6) Feldhusen F, Braunbeck T, Wallner F. *Dysphagia after eating sea foods Pyrifrom sinus foreign body with perforation and abscess of the parapharyngeal space. HNO* 1999;47:746-7.
- 7) Herzon FS. *Needle aspiration of nonperitonsillar head and neck abscesses. Arch Otolaryngol Head Neck Surg* 1988;114:1312-5.
- 8) Simon DM, Richel TO. *Clinical infections and nonsurgical treatment of parapharyngeal space infections complicating throat infection. Reviews of infectious disease* 1989;11 (6): 975-82.
- 9) Scott BA, Stienberg CM. *Deep neck space infections. In: Baily BJ. Head & Neck Otolaryngology Philadelphia; Lippincott Company* 1993;738-53.