

두개저, 부비동, 하비갑개, 비중격에 광범위하게 침범된 다골성 섬유성 이형성증 1례

인제대학교 의과대학 이비인후과학교실
최익수 · 오지청 · 전병훈 · 안병주

A Case of Polyostotic Fibrous Dysplasia of the Skull Base, Paranasal Sinus, Inferior Turbinate and Septum

Ick Soo Choi, MD, Ji Cheng Oh, MD, Byung Hoon Jun, MD and Byoung Ju Ahn MD

Department of Otolaryngology, Inje University College of Medicine, Seoul Paik Hospital, Seoul, Korea

—ABSTRACT—

Fibrous dysplasia is considered as a benign disease of the bone having an unknown etiology, characterized by a slow progression. Medullary bone that is replaced by mildly to highly cellular tissue composed of irregular trabeculae of woven bone and spindle-shaped fibroblasts. Craniofacial involvement frequently affects the maxilla and frontal bone and induced local facial swelling, facial asymmetry and exophthalmos. Currently three general subtypes of disease are recognized : monostotic, polyostotic, and McCune-Albright syndrome. We present 15-year-old male with left proptosis, superior eyelid swelling and nasal obstruction. Our case demonstrated an extensive bony lesion involving bilateral frontal, ethmoid, sphenoid sinuses, left maxillary bone, inferior turbinate, septum, and skull base. Hence we report a case of polyostotic fibrous dysplasia with extensive bony involvement. (J Clinical Otolaryngol 2002;13:220-224)

KEY WORDS : Fibrous dysplasia, Polyostotic · Panasal sinuses · Skull base · Nasal cavity.

서	본	70%	10~25%
(trabeculae)	100%	30%	50%
1-5)	McCune - Albright syndrome	3%	1)6)7)
: 2002 8 12	1)3)	2.5%	7.5%
: 2002 10 2			
: , 100 - 032	2)3)		
2가 85			
: (02) 2270 - 0070~2, 0075			
: (02) 2270 - 0073			
E - mail : cisoo99@yahoo.co.kr			1)

2) , 3) , 4) 2 13 2
 5) 가 , 39 가
 0.9
 13
 1 가
 증 례

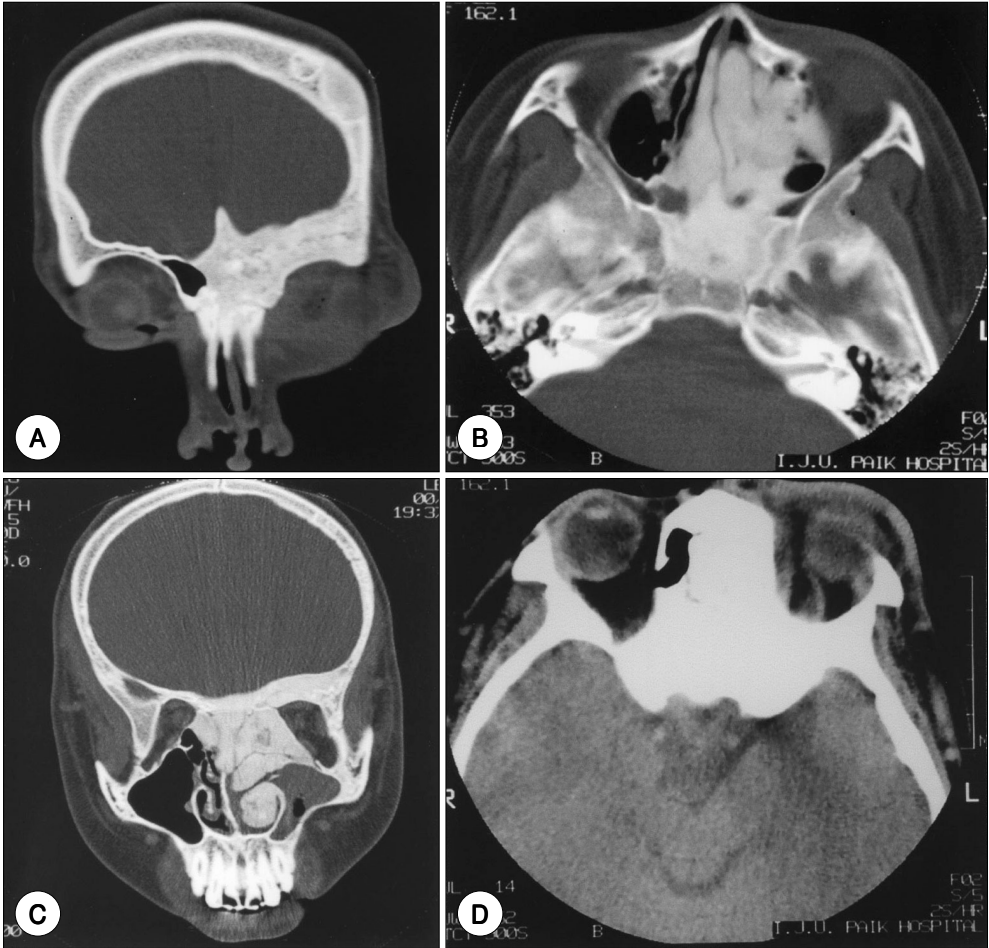


Fig. 1. Coronal (A), (C) and axial (B), (D) CT scan of paranasal sinus : The mass is extended to skull base, bilateral frontal, ethmoid, sphenoid sinuses, left maxillary bone, septum, left middle and inferior turbinate (ground glass appearance). D : shows left periorbital swelling.

가 (ground glass appearance) 가 (Fig. 1). 2 가 0.5 cm silicon tube 가 (Fig. 2).

가 (Fig. 3), 1 가 1 8 가 (Fig. 3),

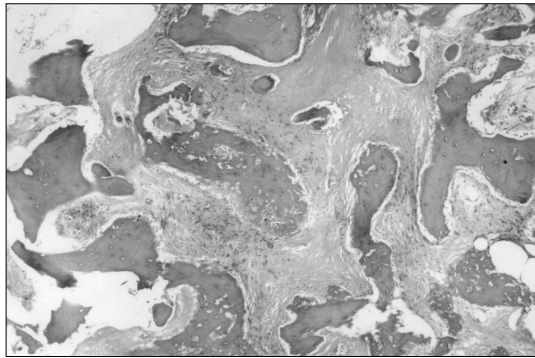


Fig. 2. Pathologic finding : The lesion is composed of dense fibrous tissue and irregular immature bone spicules (H&E $\times 40$).

고찰

Jaffe⁸⁾
 1938 Lichtenstein
 1942 Lichtenstein
 가 Albright
 1)6)9)10)

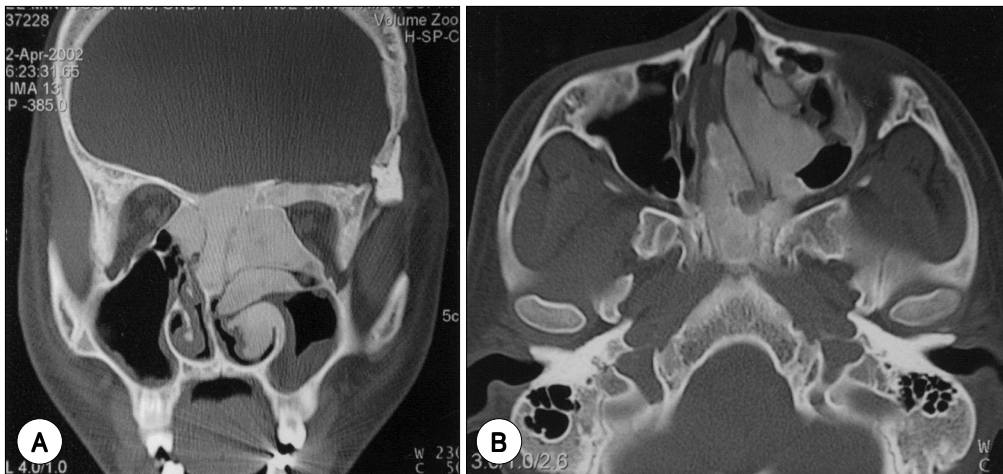


Fig. 3. Coronal (A) and axial (B) CT scan of paranasal sinus in postoperative 1 years 8months : There is no interval change (ground glass appearance).

: , , ,

1

(complete spontaneous involution)

10~25%, 50~100%

3)

3)

T1

T2

가

5) Lustig

6)

7)

가

(mesenchyme) (intramembranous ossific-

1)

ation)

가

1)5)

가

가

6)

가

가

가

5)13)

가

가

가

2)

3)

3)

가

가

가

가

가

가

가

3-5)

가

0.5%

12)

가 가

12)

1

가 가

가

중심 단어 :

REFERENCES

- 1) Park SK, Jang SH, Yoon HK. *A case of polyostotic fibrous dysplasia of the temporal bone and sphenoid sinus. J Clinical Otolaryngol* 2000;11:319-22.
- 2) Lee KC, Park SO, Lee YB, Yang JY. *A case of monostotic fibrous dysplasia of the frontal sinus. Korean J Otolaryngol* 1997;40:1031-4.
- 3) Lee KH, Kang JM, Lee SK, Ju YH. *A case of fibrous dysplasia of the ethmoid bone forming intracranial cyst. Korean J Otolaryngol* 1999;42:1311-5.
- 4) Song KT, Kim SW, Choung WC, Kim KI. *A case of monostotic-type fibrous dysplasia in the sphenoid sinus. Korean J Otolaryngol* 1997;40:1495-500.
- 5) Cho JH, Kim JM, Ro WY, Kim MS. *Three cases of fibrous dysplasia involving the paranasal sinuses. Korean J Otolaryngol* 1999;42:1316-20.
- 6) Lustig LR, Holliday MJ, McCarthy EF, Nager GT. *Fibrous dysplasia involving the skull base and temporal bone. Arch Otolaryngol Head Neck Surg* 2001;127:1239-47.
- 7) Chong VF, Khoo JB, Fan YF. *Fibrous dysplasia involving the base of the skull. AJR Am J Roentgenol* 2002;178:717-20.
- 8) Lichtenstein L, Jaffe HL. *Fibrous dysplasia of bone. Arch Pathol* 1942;3:777-816.
- 9) Stefanovie P, Djerje D. *Maxillary sinus fibrous dysplasia. J Rhinol* 1998;5:152-4.
- 10) Heller AJ, DiNardo LJ, Massey D. *Fibrous dysplasia, Chondrosarcoma, and McCune-Albright syndrome. Am J Otolaryngol* 2001;22:297-301.
- 11) Edgerton MT, Persing JA, Jane JA. *The surgical treatment of fibrous dysplasia. Ann Surg* 1985;202:459-79.
- 12) Gross CW, Montgomery WW. *Fibrous dysplasia and malignant degeneration. Arch Otolaryngol* 1967;85:653-7.
- 13) Pasquini E, Compadretti GC, Sciarretta V, Ippolito A. *Transnasal endoscopic surgery for the treatment of fibrous dysplasia of maxillary sinus associated to aneurysmal bone cyst in a 5-year-old child. Int J Pediatr Otorhinolaryngol* 2002;62:59-62.