

후두에 발생한 신경초종 1예

김태형 · 김수진 · 조승배 · 조영홍 · 김진홍

A Case of Laryngeal Schwannoma

Tae Hyung Kim, MD, Su Jin Km, MD, Seung Bae Cho, MD,
Young Hong Cho, MD and Jin Hong Kim, MD

Department of Otolaryngology-Head & Neck Surgery, Dae Dong Hospital, Busan, Korea

-ABSTRACT-

Schwannoma is a benign well-encapsulated tumor arising from the sheath of Schwann cell. It is known to recur rarely after resection.

Since it is common at the head and neck region, schwannoma must be included in the differential diagnosis. It is common at the head and neck region but a few cases was reported in the larynx. We have experienced a 65-year-old woman who had 6-month history of progressive vocal change. We recognized a benign mass at supraglottic area on CT and MRI. The tumor was successfully removed through lateral thyrotomy approach. So we report this case of laryngeal schwannoma in a patient who recovered voice after surgery. (J Clinical Otolaryngol 2002;13:140-143)

KEY WORDS : Larynx · Neurilemmoma.

서론

65

1

가

1935 Stout schwannoma 10

1)

2)

가

증례

: 2002 3 18

: 2002 4 23

: , 607 - 711

65

가 1998 3 30

6

530 - 1

: (051) 554 - 1233 · : (051) 554 - 5415

. 1997 9

가

E - mail : DDENT@chollian.net

가

1

가
 가
 T1
 , T2 가 (Fig. 1).
 2x2.5x3 cm (Fig. 2). 9
 가
 2 가
 5

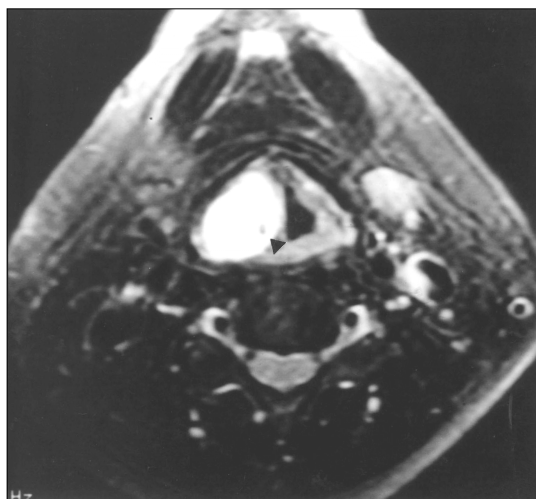


Fig. 1. MRI finding. T2-weighted axial MRI shows a homogeneous high signal intensity mass (arrow head).

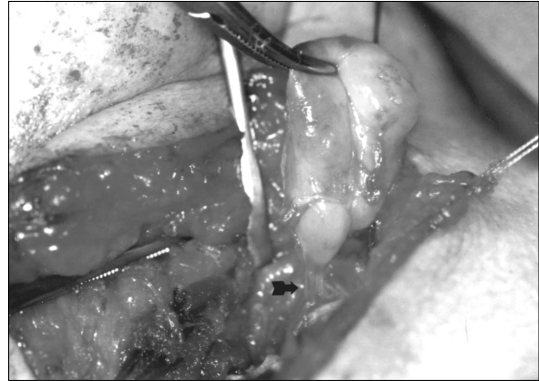


Fig. 2. Intraoperative finding. Well-encapsulated yellowish mass. It was originated from superior laryngeal nerve (bold arrow).

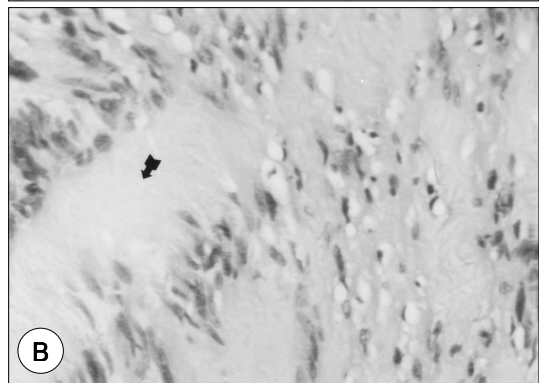
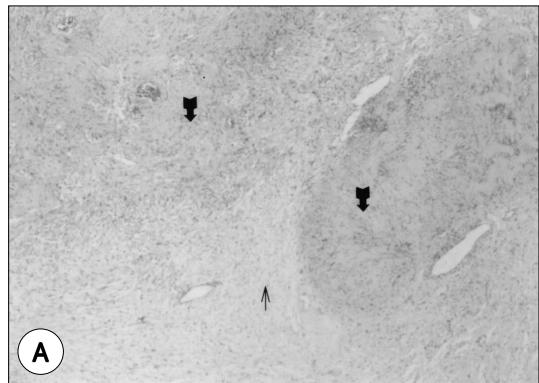

Fig. 3. Histopathological findings. A : Highly cellular Antoni A (bold arrow) areas have central location and loose myxoid, Antoni B (thin arrow) areas have peripheral location (H-E stain, x 40). B : Antoni A areas show Verocay bodies (bold arrow), the nuclear-free zone of processes that lie between the regions of nuclear palisading (H-E stain, x 200).

Antoni - A Antoni - B가
Verocay body가
(Fig. 3).

고 찰

25%

6 가 1)3-7) 가 9) 가

2) 가

가 4) 11)12) 가

가, 13) 가

가 3) 가

가 14) 가

1) 가

10) 가

가 7 9 가

Antoni - A Antoni - B

Antoni - A Verocay body

Antoni - B

Antoni - A Antoni - B가 8) 1

3cm가

결 론

중심 단어 :

REFERENCES

- 1) Yoo BH, Park HW, Ko CG, Cju KC, Kim SY. *A case of laryngeal schwannoma*. *Korean J Otolaryngol* 1990;33:1028-32.
- 2) Hong WP, Lee WS, Kim HO, Chung KH. *A clinical study of schwannoma in the head and neck*. *Korean J Otolaryngol* 1988;31:461-5.
- 3) Seo YI, Nam SY, An KH, Kim SY, Lee KS. *Extracranial nerve sheath tumors of the head and neck*. *Korean J Otolaryngol* 1997;40:908-13.
- 4) Suh JS, Lee HC, Han TH, Park MH, Park YS. *A case of neurilemmoma of the larynx*. *Korean J Otolaryngol* 1987;30:293-8.
- 5) Cho SH, Kim HT, Yoo WJ, Kim MS. *Malignant peripheral nerve sheath tumor of the larynx*. *Korean J Otolaryngol* 1997;40:450-6.
- 6) Cho SH, Kim HT, Kim MS, Sun DI, Lee DH, Jung MK, et al. *The nonsquamous cell tumors of the larynx*. *Korean J Otolaryngol* 1998;41:918-24.
- 7) Choi YS, Jun JH, Kwon SW, Kim IS. *A case of neurilemmoma of the larynx*. *Korean J Otolaryngol* 2001;44:780-2.
- 8) Kim YK, Chung KH, Kim JH, Yoon YJ. *Two cases of neurilemmoma of the external auditory canal*. *Korean J Otolaryngol* 1996;39:870-4.
- 9) George T. Nager. *Acoustic neurinomas. Pathology and differential diagnosis*. *Arch Otolaryngol* 1969;89:252-79.
- 10) Schaeffer Bt, Som PM, Biller HF, Som ML, Arnold LM. *Schwannoma of the larynx*. *Otolaryngol Head Neck Surg* 1986;8:469-72.
- 11) Park HS, Hur J, Jo MJ, Kim KS. *A case of schwannoma of the tongue*. *Korean J Otolaryngol* 1997;40:314-7.
- 12) Oberman HA, Sullenger G. *Neurogenous tumors of the head and neck*. *Cancer* 1967;20:1992-2001.
- 13) Chang SC, Schi YM. *Neurilemmoma of the vagus nerve: A case report and brief literature review*. *Laryngoscope* 1984;94:946-9.
- 14) Sanghvi V, Lala M, Borges A, Rodrigues G, Pathak KA, Parikh D. *Lateral thyrotomy for neurilemmoma of the larynx*. *J Laryngo Otol* 1999;113:346-8.