

수술방법

1 : 100,000 epinephrine 가
2% lidocaine
(superior and inferior margin)
(lateral margin)

(Fig. 1). 5.0 PDS
(inner lining)
(advancement) (outer lining)
(dog-ear)
(deepithelization) (Fig. 2), V-Y
5.0 Nylon (Fig. 3).
drain

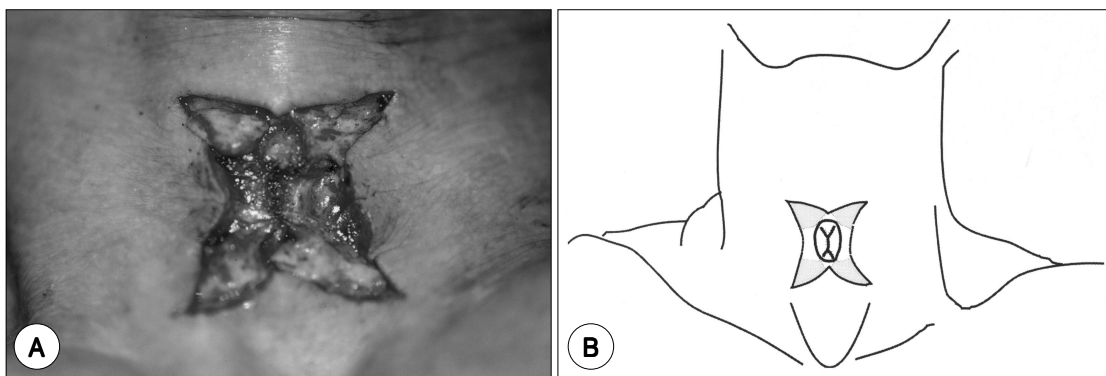
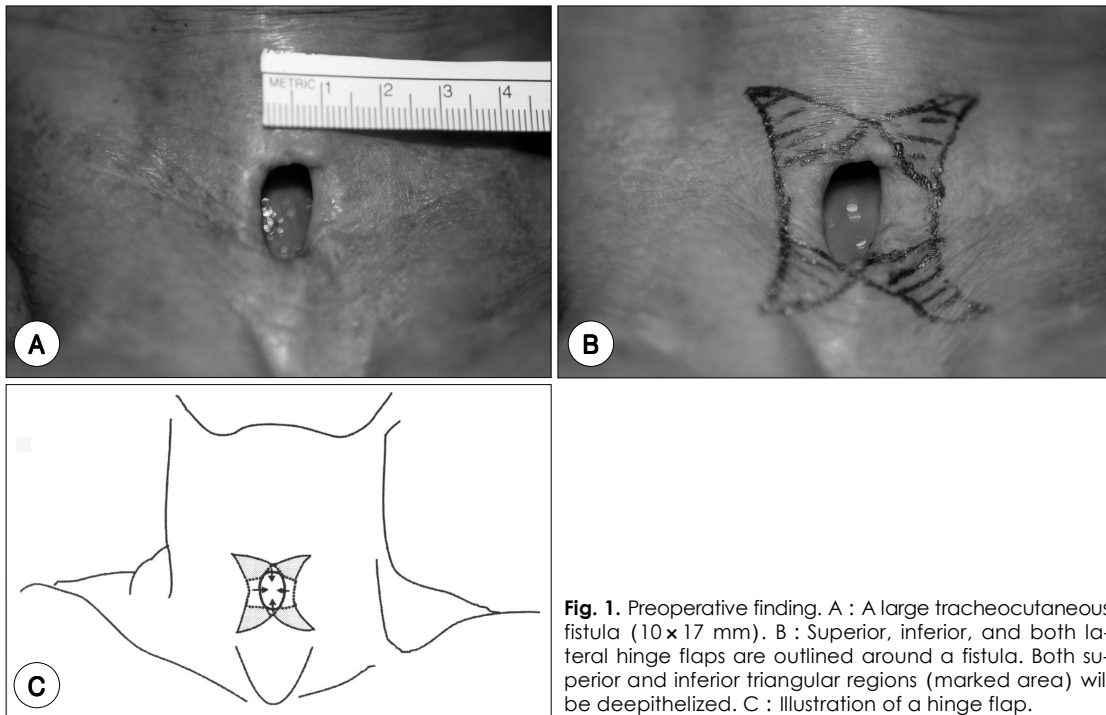
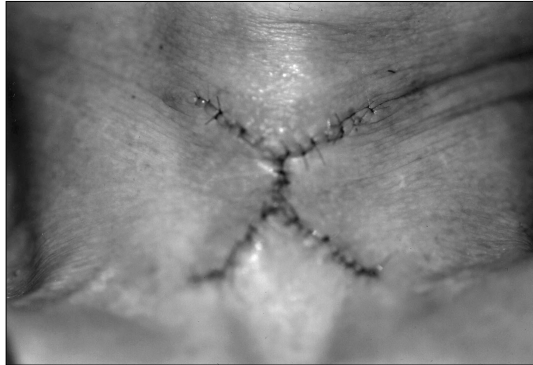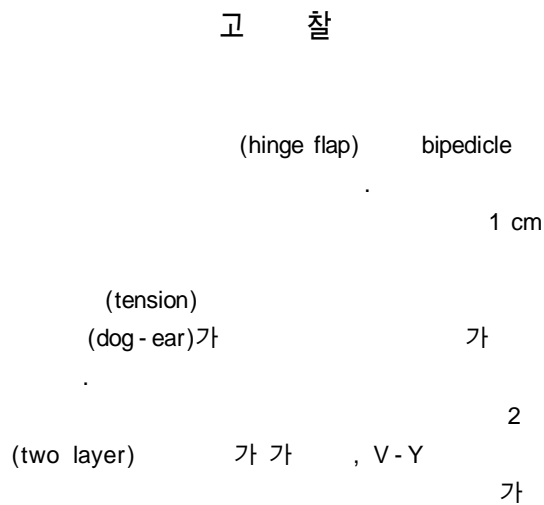




Fig. 3. Immediate postoperative finding after the closure of the outer layer by V-Y advancement flap.

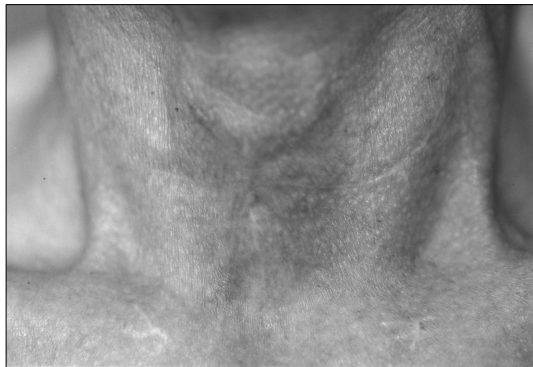

Fig. 4. Good cosmetic and functional results 3 months after closure using a turn-over hinge flap and a V-Y advancement flap.



V - Y

가

. Keenan 7)

요 약

V - Y

중심 단어 :

REFERENCES

- 1) White AK, Smitheringale AJ. *Treatment of tracheocutaneous fistula in children. J Otolaryngol* 1989;18:49-52.
- 2) Kulber H, Passy V. *Tracheotomy closure and scar revisions. Arch Otolaryngol* 1972;96:2-26.
- 3) Jackson C, Babcock WW. *Plastic closure of tracheocutaneous fistula. Surg Clin N Am* 1934;14:199-221.
- 4) Lawson DW, Grillo HC. *Closure of persistent tracheal stoma. Surg Gynecol Obstet* 1970;30:495-6.
- 5) Vecchione TR, Pickering PP. *The subcutaneous Z-plasty. Plast Reconstr Surg* 1975;51:579-80.
- 6) Goldsmith AJ, Abramson AL, Myssiorek D. *Closure of tracheocutaneous fistula using a modified cutaneous Z-plasty. Am J Otolaryngol* 1993;14:240-5.
- 7) Keen JP, Snyder III G, Lehmann WB, Ruiz JW. *Management of tracheocutaneous fistula. Arch Otolaryngol* 1978;104:530-1.
- 8) Stern Y, Cosenza M, Walner DL, Cotton RT. *Management of persistent tracheocutaneous fistula in the pediatric age group. Ann Otol Rhinol Laryngol* 1999;108:880-3.
- 9) Fisher SR. *Closure of tracheocutaneous fistula with perichondrial flap following cricothyroidotomy. Laryngoscope* 1991;101:684-5.
- 10) Jacobs. *Bipedicle delayed flap closure of persistent radiated tracheocutaneous fistulas. J Surg Oncol* 1995;59:196-8.
- 11) Berenholz LP, Vail S, Berlet A. *Management of tracheocutaneous fistula. Arch Otolaryngol Head Neck Surg* 1992;118:869-71.