

측두골과 접형동에 발생한 다골성 섬유성 이형성증 1례

박성국¹ · 장성호¹ · 윤혜경²

A Case of Polyostotic Fibrous Dysplasia of the Temporal Bone and Sphenoid Sinus

Seong Kook Park, MD¹, Seong Ho Jang, MD¹ and Hye Kyung Yoon, MD²¹Department of Otolaryngology-Head & Neck Surgery and ²Pathology, College of Medicine, Inje University, Pusan, Korea

- ABSTRACT -

Fibrous dysplasia is a slowly progressive, benign disorder characterized by fibrous tissue replacement of skeleton. The etiology is unknown, but is now believed to be a developmental error in which primitive fibrous tissue proliferates within the bony medulla and enchroaches up on the cortex. Two forms of fibrous dysplasia are recognized : monostotic form - involvement of a single bone (70%) and polyostotic multifocal form – involvement of multiple bones (30%). The temporal bone is affected only 18% of cases and the lesion are more frequently monostotic than polyostotic forms, which will frequently cause an acquired stenosis of external auditory canal and develop external canal cholesteatoma. Authors experienced a case of fibrous dysplasia of temporal bone and sphenoid sinus in 17 years old female, and reported this case with brief review of literatures. (*J Clinical Otolaryngol* 2000;11:319-322)

KEY WORDS : Fibrous dysplasia · Temporal bone · Sphenoid sinus.

서 론

(polyostotic form),

McCune - Albright sy -

ndrome¹⁻³⁾

18%

¹⁾²⁾⁴⁾가¹⁾

가

70%

(monostotic form),

30%

: 2000 9 1

: 2000 10 20

: , 614 - 735

633 -

증 례

165

: (051) 890 - 6379 · : (051) 892 - 3831

E - mail : sinus4@chollian.net

17

6

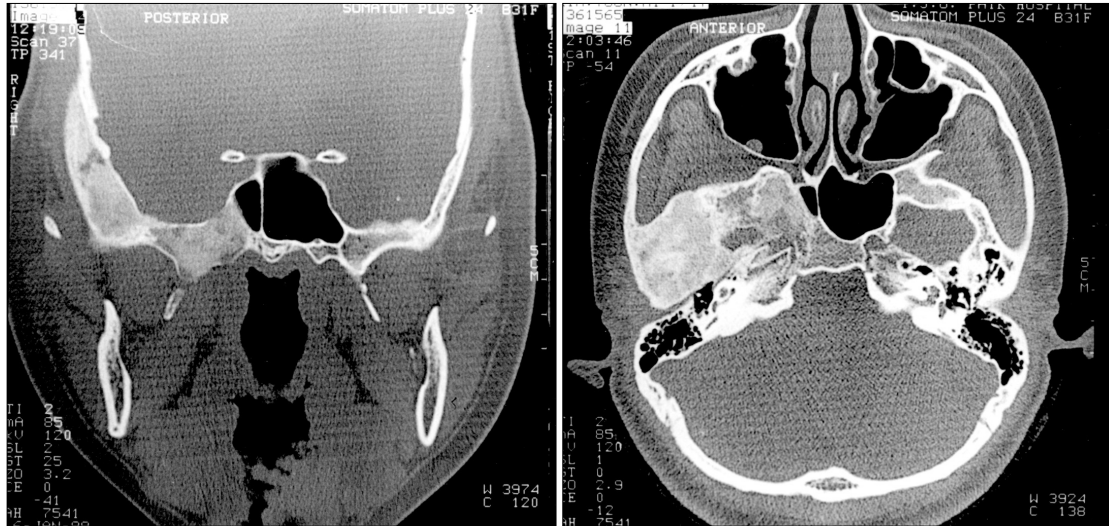

Fig. 1. Temporal bone CT scan showed a fibrous dysplasia involving temporal bone and sphenoid sinus (ground-grass appearance).

5 dB, 60 dB

(Fig. 1).

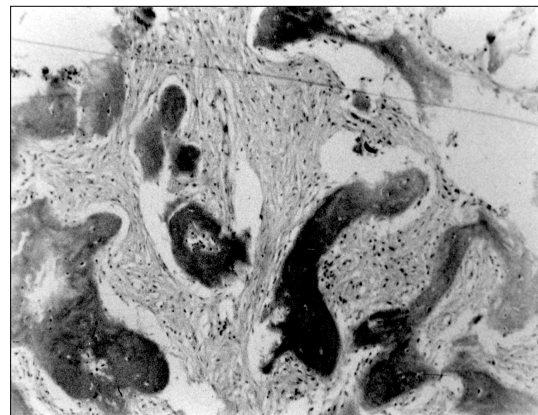


Fig. 2. Photomicrophic of mass in external auditory canal. Irregular, woven bony trabeculae without osteoblastic rimming are observed in the fibrous stroma with moderate cellularity (H & E, ×100).

가

(Fig. 3).

고 찰

(Fig. 2). 5
1 6

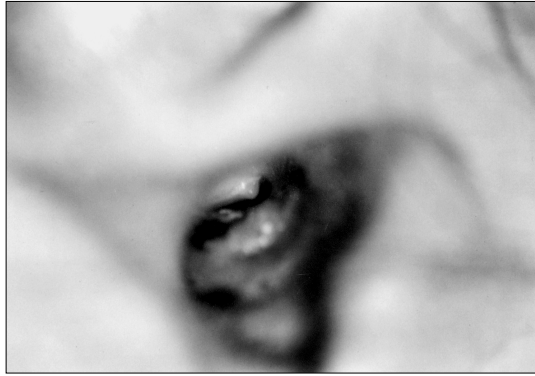


Fig. 3. After surgery, tympanic membrane was seen in some narrowed external auditory canal.

4)
2) 5)
6) 7)
가 가
1)
(membranous ossification)
3가
(monostotic fibrous dysplasia)
70%
4)
(polyostotic fibrous dysplasia)
30%
50%
100%
8) 가
McCune - Albright syndrome
3% 4)
18%

1
4) Kessler
10%
50%
100%
2)4)
9)
es¹⁰⁾
ground - grass
(56%),
(23%),
(cystic) 3가
(osteblast)
가 C - shape, ' jigsaw puzzle '
' Chinese letter ' 11)
가
12)
14)
13)
가
9) Na -
가
15)16)

hwartz Alpert¹⁷⁾ 가 0.5%
Gross Montgomery¹⁸⁾

Paget's disease,

15)16)

7)17)

중심 단어 :

Sc-

REFERENCES

- 1) Kessler A, Wolf M, Ben-Shoshan. *Fibrous Dysplasia of the Temporal Bone Presenting as an Osteoma of the External Auditory Canal. Ear Nose and Throat J* 1990;69:197-9.
- 2) Lichtenstein L, Jaffe HL. *Fibrous dysplasia of bone. Arch Pathol* 1942;3:777-816.
- 3) Djeric D, Stefanovic P. *Fibrous dysplasia of the temporal bone and maxillofacial region associated with cholesteatoma of the middle ear. Auris Nasus Larynx* 1999;26:79-81.
- 4) Shin SO, Yang SK, Yoo IS. *Polyostotic Fibrous Dysplasia with Cholesteatoma on External Auditory Canal and Mastoid. Korean J Otolaryngol* 1998;41:1082-6.
- 5) Carl S. *Fibrous dysplasia of facial bones. Arch Otolaryngol* 1956;64:293-306.
- 6) Schlumberger HG. *Fibrous dysplasia of the single bone. Mil Surg* 1946;99:504-27.
- 7) Albright F. *Syndromes characterized by osteitis fibrosa disseminata, areas of pigmentation and endocrine dysfunction with precocious puberty in female. N Engl J Med* 1937;216:727-30.
- 8) Windolz F. *Cranial manifestations of fibrous dysplasia of bone. Am J Roentgenol* 1947;58:51-63.
- 9) Song KT, Kim SW, Choung WC, Kim KI. *A Case of Monostotic-Type Fibrous Dysplasia in the Sphenoid Sinus. Korean J Otolaryngol* 1997;40:1495-500.
- 10) Fries JW. *The roentgen features of fibrous dysplasia of the skull and facial bone: Critical analysis of thirty-nine pathologically proven cases. AJR* 1957;77:71-88.
- 11) Michelle RY, Samuel HS. *Temporal bone fibrous dysplasia and cholesteatoma leading to the developement of a parapharyngeal abscess. J Laryngol Otol* 1994;108:51-3.
- 12) Krishna TVR, Bippon CV, Anthony FJ, David VG. *Fibrous dysplasia of the temporal bone. Ann Otol Rhinol Laryngol* 1994;103:74-6.
- 13) Eum JH, Chung WK, Park SI, Park MH. *A Case of Fibrous Dysplasia of the Temporal Bone. Korean J Otolaryngol* 1996;7:415-21.
- 14) Eugene WB, Cliff AM, Michael JM, Alfred W. *Fibrous dysplasia of the temporal bone : Imaging finding. AJR* 1995;164:679-82.
- 15) Nager GT, Kennedy DW, Kopstein E. *Fibrous dysplasia: A review of the disease and its manifestations in the temporal bone. Ann Otol Rhinol Laryngol* 91 (suppl) 1982;91:1-52.
- 16) Nager GT, Holliday MJ. *Fibrous dysplasia of the temporal bone, update with case reports. Ann Otol Rhinol Laryngol* 1984;93:630-3.
- 17) Schwartz DT, Alpert M. *The malignant transformation of fibrous dysplasia. Am J Med Sci* 1964;247:1-20.
- 18) Gross CW, Montgomery WW. *Fibrous dysplasia and malignant degeneration. Arch Otolaryngol* 1967;85:653-7.