

우측 외이도에 발생한 제1형 신경섬유종증 1례

이병돈 · 한동열 · 김희중 · 장혁순

A Case of Neurofibromatosis Type I on Right External Auditory Canal

Byung Don Lee, MD, Dong Yul Han, MD, Hee Joong Kim, MD and Hyuck Soon Chang, MD

Department of Otolaryngology, College of Medicine, Soonchunghyang University, Seoul, Korea

- ABSTRACT -

Neurofibromatosis is a group of related genetic disorder of neuroectodermal tissue characterized by CNS, PNS tumors and disorders, cafe-au-lait spots, generalized cutaneous neurofibromata, skeletal deformities and endocrine abnormalities. It involves in head and neck area about 25 -30%. In 1987, according to genetics, National Institute of Health clarified the two main types of neurofibroma. Recently, the authors experienced a case of neurofibromatosis type I on right external auditory canal and treated with surgery and pathologic diagnosis was benign neurofibroma. (**J Clinical Otolaryngol 2000;11:304-308**)

KEY WORDS : Neurofibroma · External auditory canal.

서 론

증 례

신경섬유종증은 중추신경계, 말초신경계, 안구, 피부, 뼈, 내분비 기관에 영향을 미치는 유전적 질환이다. 1987년 유전학 연구에 따르면, 두 가지 주요 유형으로 분류된다. 최근 저자들은 우측 외이도에 발생한 제1형 신경섬유종증 1례를 경험하였고, 수술적 치료 후 병리학적 진단을 통해 양성 신경섬유종증임을 확인하였다. (**J Clinical Otolaryngol 2000;11:304-308**)

키워드 : 신경섬유종증, 외이도.

Correspondence: Byung Don Lee, MD
: (02) 709 - 9363 · : (02) 794 - 9628
E - mail : BDLEE12@hosp.sch.ac.kr

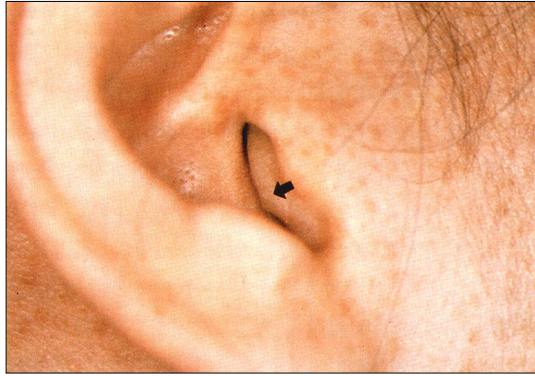

Fig. 1. Obstructing mass on the right external auditory canal.

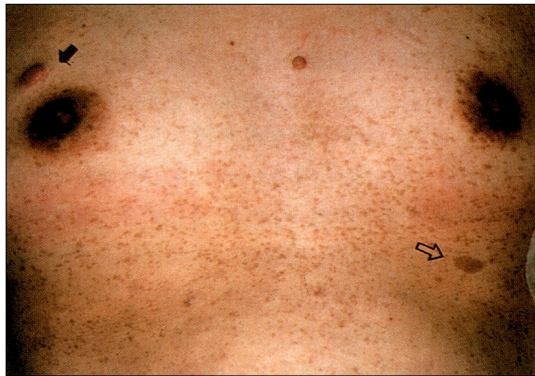

Fig. 2. Photograph showing the numerous freckling, subcutaneous peripheral neurofibroma (black arrow) and cafe-au-lait spot (open arrow) on the anterior chest.

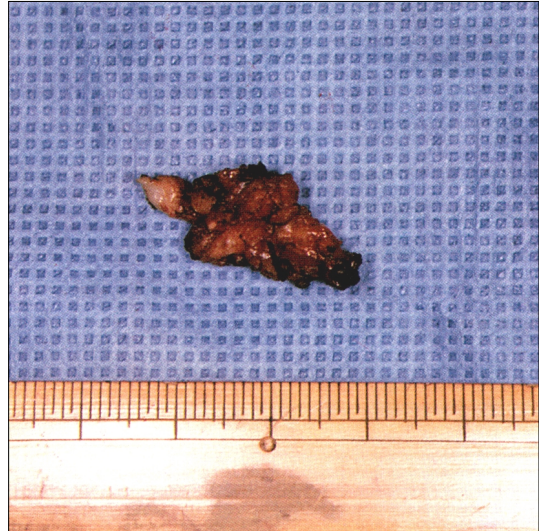

Fig. 3. Gross finding of removed tumor (1 x 1 x 1.5 cm).

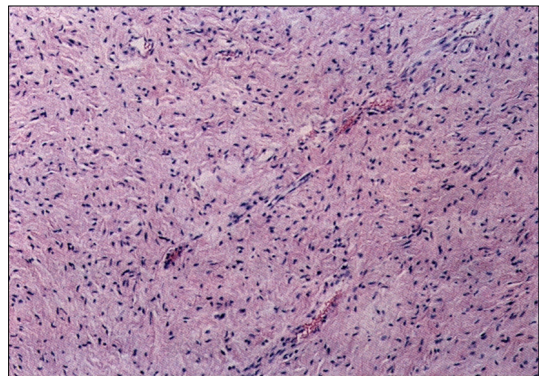


Fig. 4. The spindle cell tumor forming nodular structures with peripheral nuclei.

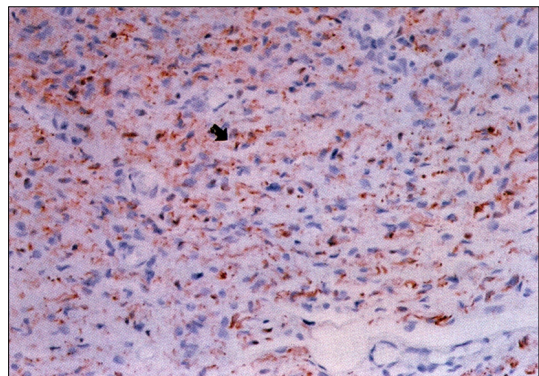


Fig. 5. Immunohistochemical stain with S-100 protein showing the reddish neurofibroma cells.

:
 .
 :
 가 ,
 .
 1 x 1 x 1.5 cm
 (Fig. 3).
 : 3
 : 가
 가
 (Fig. 4).
 가 S - 100 protein
 (Fig. 5).

고찰

(NF)

cafe-au-lait spots,

1882 Von Recklinghausen

1987 National Institute of Health(NIH) Consensus Development Conference

1 NF1 2가

5 mm

15 mm cafe-au-lait

6

2 NF2

1 plexiform neurofibroma . Lisch nodule NF1 85%

2 Lisch nodule NF2

NF2 30

, NF1 .⁴⁾ NF1

17 , NF2 22

1

2 (NF2) 가 1 NF2 30%

8 (i.e., acoustic neuroma) . CT scan 15%

NF1 가

NF1

enhanced brain MRI . cafe-au-lait spots 가

Schwann Schwann 가⁶⁾ 10%

.¹⁾

Lisch iris nodule, cafe-au-

lait spots, 가
 , , 가
 , , 가
 , 7) 가
 가 30% .¹⁾ 40 가 .
 가 .
 ,³⁾ 가
 5 가
 5 가
 가 가 gado -
 linium enhanced MRI, , CT, ABR
 network .
 , , .
 , , , , .
 , , , , .
 , , , , .
 , , , , .
 , Horner , , , , .
 cafe - au - lait spots , , 가
 가 가 가
 ,⁵⁾ 가 , , 가
 , , , , .
 , , , , .
 , , , , .
 , Horner , , , , .
 cafe - au - lait spots , , 가
 가 가 가
 ,¹⁰⁾ 가

중심 단어 :

REFERENCES

- 1) Kimmelman CP. *Otolaryngologic aspects of neurofibromatosis. Arch Otolaryngol* 1979;105(12):732-6.
- 2) Putney FJ, Moran JJ, Thomas GK. *Neurogenic tumors of head and neck. Laryngoscope* 1964;74:1037-59.
- 3) Lee JS, Yoo TS, Hong SK, Yang HS. *A case of neurofibromatosis type I. Korean J Otolaryngol* 1992;35:133-8.
- 4) Miyamoto RT, Campbell RL. *Contemporary Management of neurofibromatosis. Ann Otol Rhinol Laryngol* 1991;100(1):38-43.
- 5) Lusting LR, Jackler RK. *Neurofibromatosis type I involving the external auditory canal. Otolaryngol Head and Neck Surg* 1996;114(2):299-307.
- 6) Hwang SK, Goh EK, Wang SG, Chon KM. *A case of large neurofibroma in left parotid and right submandibular*

⁸⁾ 가
 Lisch nodule 6 94%
 , 가 가
 ,⁹⁾
 Lisch nodule
 Schwann 가

- region accompanied by multiple neurofibromatosis. 1987; 30:629-34.*
- 7) McKennan KX. *Neurofibromatosis type -a rare case resulting in conductive hearing loss. Otolaryngol Head and Neck Surg 1991;104(6):868-72.*
 - 8) Kim KS, Cha IS, Lee KS. *Right postauricular plexiform neurofibroma in Von Recklinghausen's disease. Korean J Otolaryngol 1983;26:563-6.*
 - 9) Riccardi VM. *Medical progress-Von Recklinghausen neurofibromatosis. The New England Journal of Medicine 1981;305(27):1617-29.*
 - 10) Jun KM, Koh HJ, Song IM. *A case of Neurofibroma of the Larynx. Korean J Otolaryngol 1982;25:566-70.*