

안와내 골막하 농양을 동반한 소아 부비동염 3례

박성국 · 조홍욱 · 박춘근

Three Cases of Pediatric Sinusitis with Subperiosteal Orbital Abscess

Seong Kook Park, MD, Hong Wook Cho, MD and Choon Keun Park, MD

Department of Otorhinolaryngology, College of Medicine, Inje University, Pusan Paik Hospital,
Pusan, Korea

- ABSTRACT -

Infections of the orbit in children usually present as a complication of sinusitis and can result in blindness and death. The treatment of orbital complication from sinusitis is surgical intervention whenever antibiotic treatment fails. Recently we experienced 3 cases of subperiosteal abscess. Two out of 3 children with proven subperiosteal abscess and sinusitis on computed tomographic scans failed antibiotic treatment and required surgical drainage. In these cases, orbital complications were resolved via transnasal endoscopic drainage of the abscess. The third case was successfully managed with intravenous antibiotics. So, we report these cases with a review of literature. (**J Clinical Otolaryngol 2000;11:298-303**)

KEY WORDS : Subperiosteal abscess · Children.

서 론

periorbita

2)

3)4)

5 1)

가

증 례

: 2000 5 1
: 2000 9 10
: , 614 - 735 633 - 증 례 1 :
165 : (051) 890 - 6375 · : (051) 892 - 3831 10 5
E - mail : sinus4@chollian.net

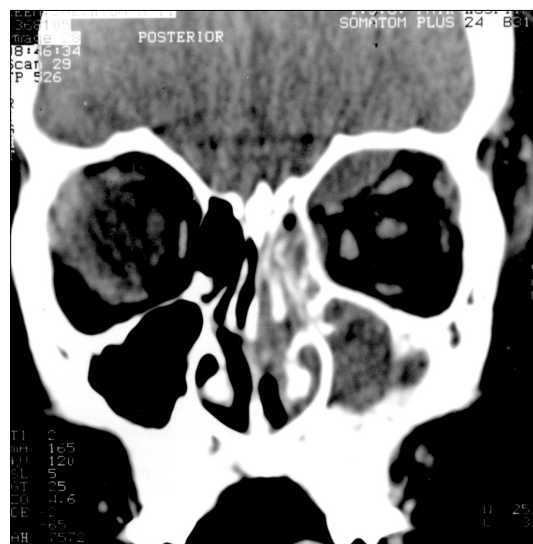


Fig. 2. Coronal PNS CT scan shows subperiosteal abscess at left orbit dilated medial rectus muscle and increased density of ethmoid and maxillary sinus.

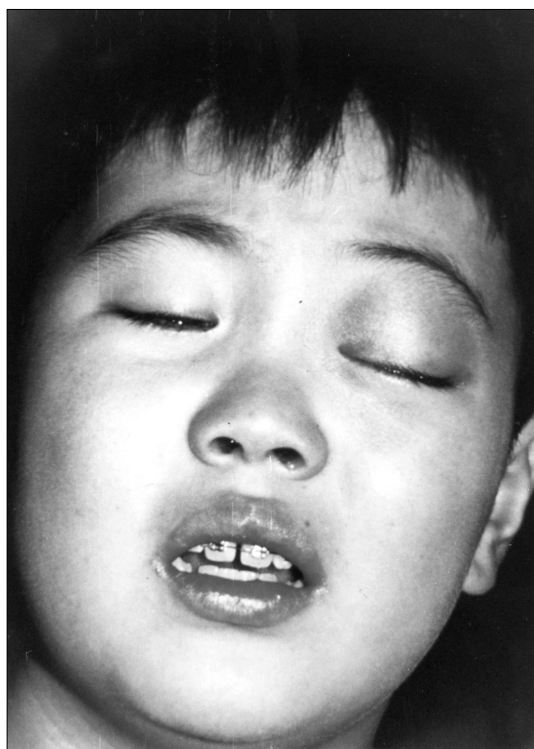


Fig. 1. A preoperative photograph shows marked swelling of left upper eyelid.

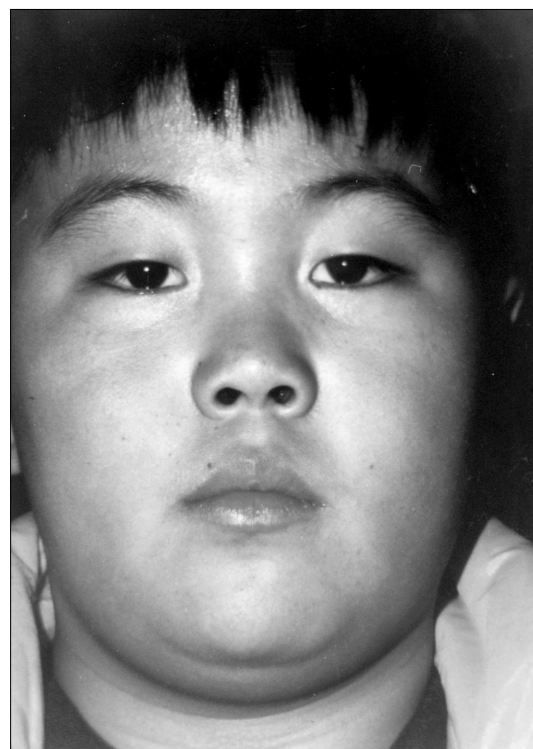


Fig. 3. A postoperative 2 months photograph shows resolved state of previous periorbital swelling.

, 25 gauge needle

2 4
6
(Fig. 3).

증례 2:

8 3
1

3
가
가

가
가

(Fig. 4).

cefmetazole sodium ne-
tilmicin sulfate 가
3

가 silastic sheet
silastic sheet

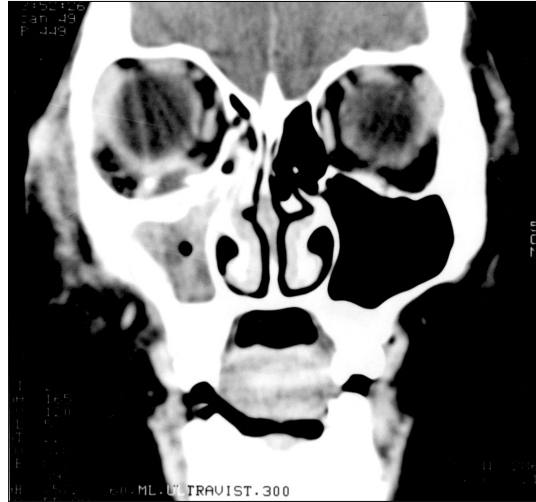


Fig. 4. Coronal PNS CT scan shows subperiosteal abscess formation at right orbital floor and increased density of right maxillary sinus.

transconjunctival approach silastic sheet
2 8
6 4

증례 3:

12 7 3
가

가

(Fig. 5). X

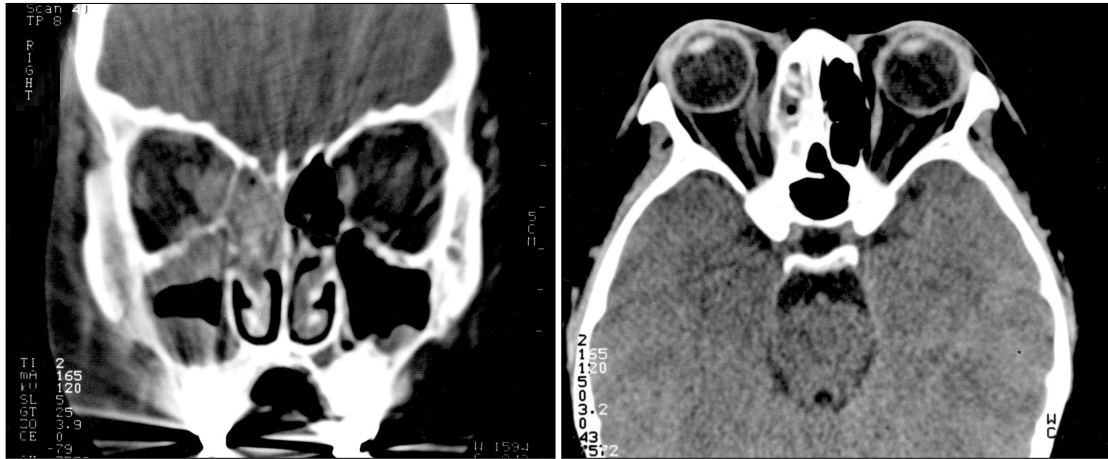

Fig. 5. Coronal PNS CT scan shows dilated medial rectus muscle and increased density of right ethmoid and maxillary sinus. Axial PNS CT scan shows subperiosteal abscess at right lamina papyracea.

cefmetazole so -
dium netilmicin sulfate
2
7
3 X
고 찰
3)
periorbita 가 5)
2) 9) 10) 11)
가 , Sajjadian 2)
3)5)
Arjmand 5) 9 , Rubin 6) 6.4 가
, Harris 7) 8.9 가
10 , 3 2 Nelson 12) Ce -
eumoniae가 , 8) Arjmand 5) H. influenza S. pn - furoxime , Sanford 13) antistaphylococcal penic -
22% , Arjmand 5) oxazole, 3 cephalosporin
, Arjmand 5)

cefuroxime clindamycin

Sajjadian ²⁾ 20/60

가 , 48

2

3

Goodwin¹⁴⁾ 24

Rubin ⁶⁾ 9

Souliere ¹⁵⁾ 5

(48

Arjm -

and ⁵⁾ 가

()

Harris⁸⁾

(emergency drainage)

(urgent drainage)

24

1

2

48

가

가 가

2

가

중심 단어 :

REFERENCES

- 1) Chandler JR, Langenbrunner DJ, Stevens ER. *The pathogenesis of orbital complications in acute sinusitis. Laryngoscope* 1970;80:1414-28.
- 2) Sajjadian A, Chundru U, Isaacson G. *Prospective application of a protocol for selective nonsurgical management of suspected orbital subperiosteal abscesses in children. Ann Otol Rhinol Laryngol* 1999;108:459-62.
- 3) Wyee JY, Lee TB, Whang SH, Hong SK. *Three cases of intraorbital subperiosteal abscess. Korean J Otolaryngol* 1996;39:306-11.
- 4) Yeo CK, Do HW, Roh HK, Kim JS. *Endoscopic surgery for intraorbital abscess: A report of one case. Korean J Otolaryngol* 1998;41:530-3.
- 5) Arjmand EM, Lusk RP, Muntz HR. *Pediatric sinusitis and subperiosteal orbital abscess formation: Diagnosis and treatment. Otolaryngol Head Neck Surg* 1993;109:886-94.
- 6) Rubin SE, Rubin LG, Zito J, Goldstein MN, Eng C. *Medical management of orbital subperiosteal abscess in children. J Pediatr Ophthalmol Strabis* 1989;26:21-7.
- 7) Harris GJ. *Subperiosteal abscess of the orbit. Arch Ophthalmol* 1983;101:751-7.
- 8) Harris GJ. *Subperiosteal abscess of the orbit. Ophthalmology* 1994;101:585-95.
- 9) Gutowski WM, Mulbury PE, Hengerer AS, Kido DK. *The role of CT scans in managing the orbital complications of ethmoiditis. Int J Pediatr Otorhinolaryngol* 1988;15:117-28.
- 10) Lemke BN, Gonnering RS, Weinstein JM. *Orbital cellulitis with periosteal elevation. Ophthalmol Plast Reconstr Surg* 1987;3:1-7.

- 11) Choi S, Lawson W, Urken ML. *Subperiosteal orbital hematoma. An unusual complication of sinusitis. Arch Otolaryngol Head Neck Surg* 1988;114:464-6.
- 12) Nelson JD. *Pocketbook of pediatric antimicrobial therapy. Baltimor: Williams & Wilkins;1990.*
- 13) Sanford JP. *Guide to antimicrobial therapy* 1992. Dallas: *Antimicrobial Therapy, Inc;1992.*
- 14) Goodwin WJ Jr. *Orbital complications of ethmoiditis. Otolaryngol Clin North Am* 1985;18:139-47.
- 15) Souliere CR, Antoine GA, Martin MP, Blumberg AI, Isaacson G. *Selective non-surgical management of subperiosteal abscess of the orbit: Computerized tomography and clinical course as indication for surgical drainage. Int J Pediatr Otorhinolaryngol* 1990;19:109-19.