

포개어 접친 전박유리피관술을 이용한 협부전층결손 재건 1례

황의기¹ · 강재용¹ · 김진평¹ · 박성근²

Reconstruction of Full Thickness Defect of the Cheek with Folded Forearm Free Flap in Buccal Mucosa Cancer

Eui Gee Hwang, MD¹, Jae Yong Kang, MD¹,
Jin Pyeong Kim, MD¹ and Seong Gun Park, MD²

¹Department of Otolaryngology-Head and Neck Surgery and ²Plastic and Reconstructive Surgery,
College of Medicine, Gyeongsang National University, Chinju, Korea

— ABSTRACT —

Resection of the buccal mucosa carcinoma usually resulted in full thickness defect of the cheek. Full-thickness defect of the cheek present a unique challenge to the reconstructive surgeon because of the simultaneous need for lining and cover. Although various methods, including split-thickness skin graft, local flap, regional flap as well as musculocutaneous flap have been described for reconstructing massive defect of cheek, these procedures have caused considerable aesthetic problem and functional morbidity of donor site. With the advent of microvascular surgical techniques, restoration of form and function is now acceptable. In recent years, we experienced a case of full-thickness defects of the cheek after resection of buccal mucosa cancer, which was successfully reconstructed by folded free radial forearm flap. (*J Clinical Otolaryngol* 2000;11:156-159)

KEY WORDS : Full thickness defect · Cheek · Folded free radial forearm flap.

서 론

5%
1)

가 가

,³⁾

(bilobed temporal flap),³⁾

가

4)

: 1999 8 24

: 2000 2 15

: , 660 - 702

90

5)

: (055) 750 - 8175 · : (055) 759 - 0613

E - mail : eghwang@gsnu.gshp.ac.kr

가

가

(5/6)

54

증례

56

가 1

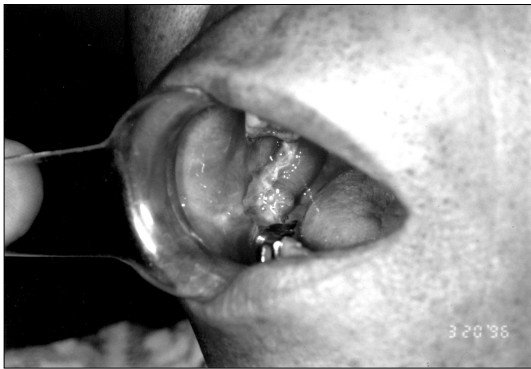

Fig. 1. Intraoral view of buccal cancer.

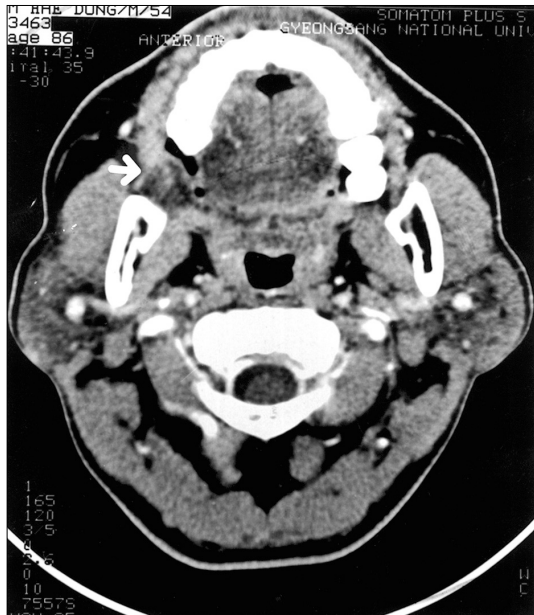


Fig. 2. Axial CT scan showing about 1.5 cm sized low soft tissue density mass (arrow) at retromolar trigone area.

8 1
 . 1995 11 22 1996 1 24
 1996 2 23

3.5 cm

가 (Fig. 1)

cm

가 (Fig. 2).

2 cm

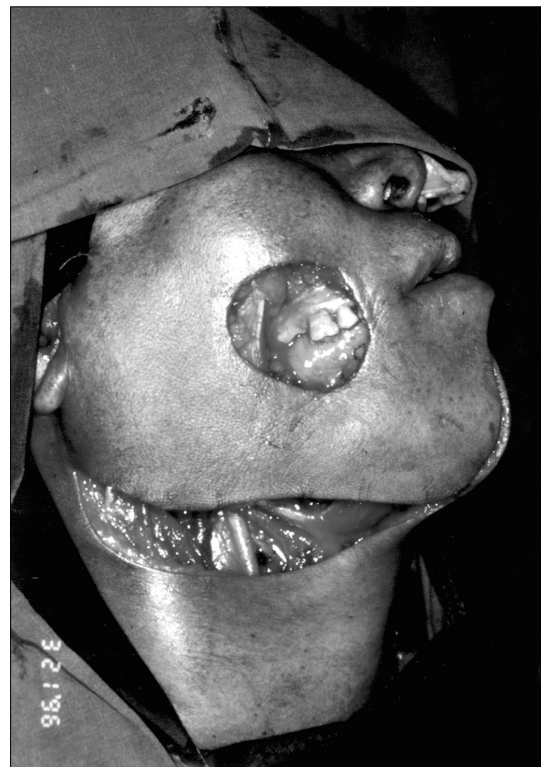


Fig. 3. Postoperative defect of cheek.

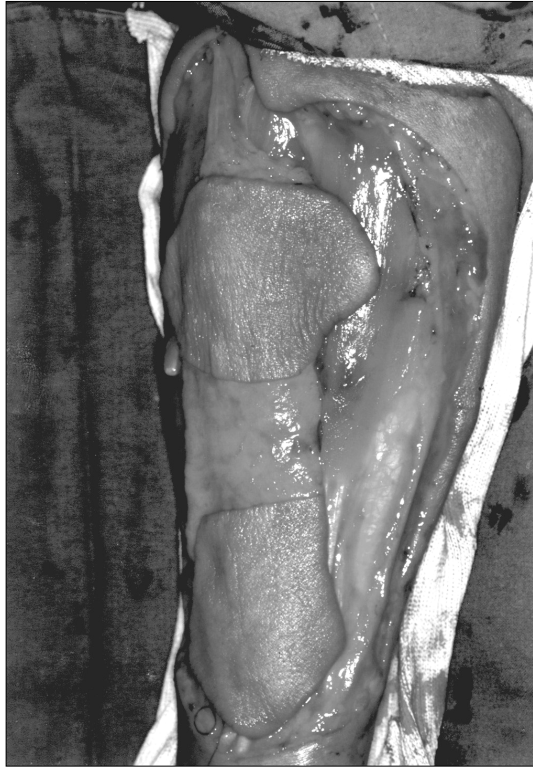

Fig. 4. Design of forearm free flap.

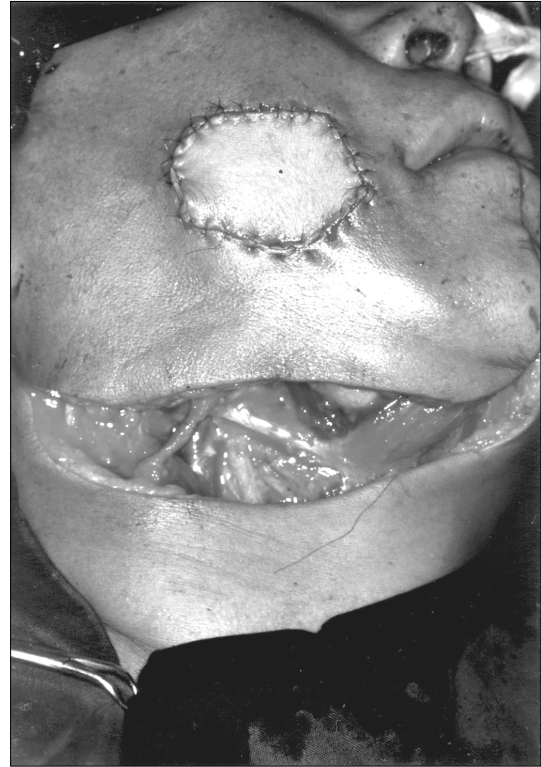


Fig. 5. Immediate postoperative figure of the flap (external).

(Fig. 3).

(Fig. 4).

(Fig. 5)

20

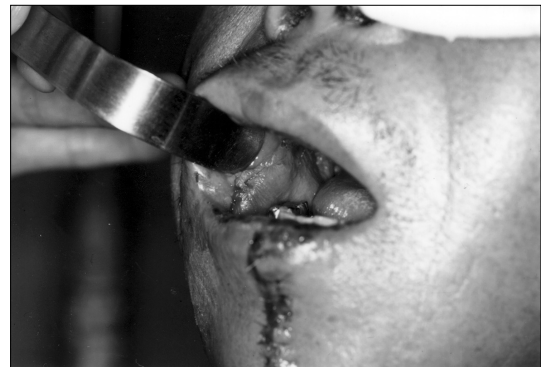

Fig. 6. Immediate postoperative figure of the flap (internal).

1)

1 1.5 cm

가

가

고 찰

