

난치성 오연 치료를 위한 Blom-Singer 튜브를 이용한 성문폐쇄술

이용식 · 최진호 · 이병철

Glottic Closure with Blom-Singer Tube Applied for Intractable Aspiration

Yong-Sik Lee, MD, Jin-Ho Choi, MD and Byeong-Cheol Lee, MD

Department of Otorhinolaryngology-Head and Neck Surgery, Korea Cancer Center Hospital, Seoul, Korea

— ABSTRACT —

Severe aspiration occasionally bring into fatal results. In mildly aspirated cases, supportive therapy or conservative operation is sufficient. However, severely aspirated patients need more invasive operation. Although a lot of operative methods have been introduced, choice of operative method is controversial. Especially, extent of operation, post-operative vocability and reversability must be considered. Authors operate on three patients for intractable aspiration due to both vocal cord palsy with glottic closure with Blom-singer tube insertion, and controlled the aspirations effectively. (J Clinical Otolaryngol 1999;10:297-299)

KEY WORDS : Glottic closure · Aspiration · Blom-singer tube.

서	론	증	례
()	1)2)	증 례 1 :	
	가 가	, M/63	
		98 4 , 3	, 98 5 7
가 .	가		
가 가			98 6 12 ,
			98 9 15
Blom - Singer	(Glottic		Blom - Singer
closure)			
: , 139 - 706 215 - 4		증 례 2 :	
: (02) 974 - 2501(2255) · : (02) 978 - 2005		, F/65	
E - mail : ysleehns@kcchsun.kcch.re.kr		97 5 2 ,	

99 6 ,
 , Blom - Singer
 99 6 4 ,
 , Blom - Singer

(Figs. 1 and 2).

(Fig. 3).

고찰

증례 3 :

, M/67
 99 7 ,
 7 14
 9, 10, 12
 , Blom - Singer

3)

방법 및 결과

Blom - Singer
 (oneway valve)
 가
 가
 Provox

4 - 0 vicryl
 4
 3 가
 가
 2, 3
 Blom - Singer
 1
 . Blom - Singer

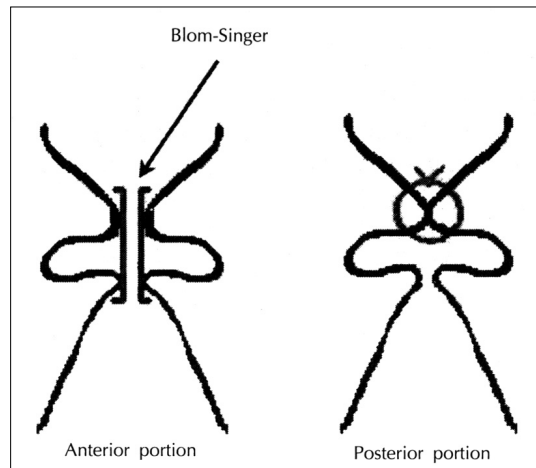


Fig. 1. Diagram of operative procedure.

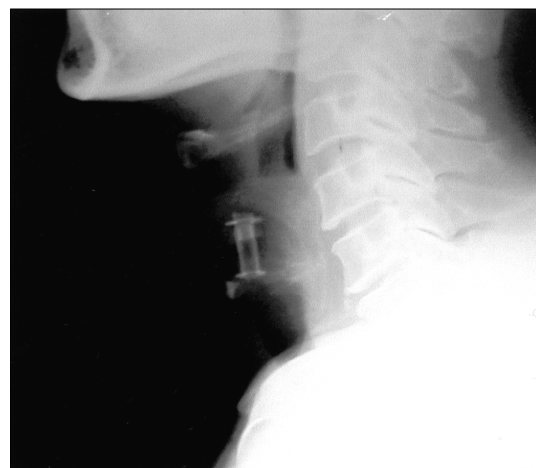


Fig. 2. Postoperative neck lateral plain radiography.

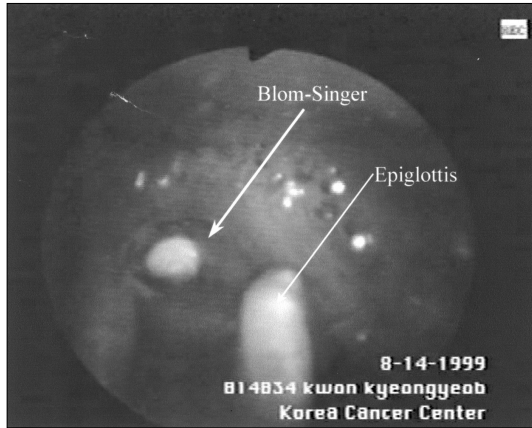


Fig. 3. Postoperative endoscopic finding.

4) Teflon 5)
 6)
 (Glottal Closure), (Supraglottic Closure),
 (Laryngeal Diversion),
 (Total Laryngectomy) 4가
 7) 8)
 가 가 , 가
 가 가 가
 가
 9) 가
 가 Henesel 10)
 18

: Blom - Singer
 7 가
 가 가
 6 7
 가
 3 가
 Blom - Singer
 가

중심 단어 : Blom - Singer tube.

REFERENCES

- 1) Awe WC, Fletcher WS, Jacob SW. *The pathophysiology of aspiration pneumonia. Surgery* 1966;60:232.
- 2) Bartlett JG, Gorbach SL. *The triple threat of aspiration pneumonia. Chest* 1975;68:560.
- 3) Bone DK, et al. *Aspiration pneumonia: Prevention of aspiration in patient with tracheostomies. Ann Thorac Surg* 1974;18:30.
- 4) Isshiki N, Okamura H, Ishkawa T. *Thyroplasty type I for dysphonia due to vocal cord paralysis or atrophy. Acta Otolaryngol* 1975;80:465.
- 5) Rontal E, et al. *Vocal cord injection in treatment of acute and chronic aspiration. Laryngoscope* 1976;86:625.
- 6) Linderman Rc. *Diverting paralyzed larynx: A reversible procedure for intractable aspiration. Laryngoscope* 1975; 85:157.
- 7) Lee KD, Lim YS, Su MS, Lee BH. *Laryngeal diversion for intractable aspiration. Korean J Otolaryngology*
- 8) Eisele DW. *Surgical approach to aspiration. Dysphagia* 1991;6:71.
- 9) Montgomery. *Surgery to prevent aspiration. Arch Otolaryngol Head Neck Surg* 1975;101:679.
- 10) Hensel M, Haake K, Vogel S. *Management of swallowing disorder and chronic aspiration by glottic closure procedure. J Neurosurg Anesthesiol* 1977;9:273.