

비중격에 원발한 소엽성 모세관 혈관종(화농성 육아종) 1례

이근섭 · 광동훈 · 김선우 · 이종담

A Case of Lobular Capillary Hemangioma on the Nasal Septum

Geun Seob Lee, MD, Dong Hun Kwak, MD, Sun Woo Kim, MD and Jong Dam Lee, MD

Department of Otolaryngology, Choonhae Hospital, Pusan, Korea

- ABSTRACT -

The lobular capillary hemangioma (pyogenic granuloma) is a rapidly growing benign haemorrhagic lesion of unknown cause. The disease usually affects a skin and an oral mucosa. It appears rare on the nasal septum, and at times difficult to differentiate from the hemangioma or the angiofibroma, etc. on the kisselbach's area. It is characterized intermittent bleeding with ulceration and nasal obstruction. Recently the authors had experienced a case of lobular capillary hemangioma from right nasal septum. The patient treated by local excision and nasal packing for control of bleeding. Histopathologic study reported lobular capillary hemangioma and no recurrences yet. (*J Clinical Otolaryngol* 1999;10:277-279)

KEY WORDS : Lobular capillary hemangioma (pyogenic granuloma) · Septum.

서 론

elbach

1

()

증 례

가 : , , 25 .

:

: 2

Kiss -

: 1999 10 5

: 1999 11 29

: , 614 - 021

873

: (051) 645 - 2181 . : (051) 645 - 8980

가

가 :

:

1 × 1 cm

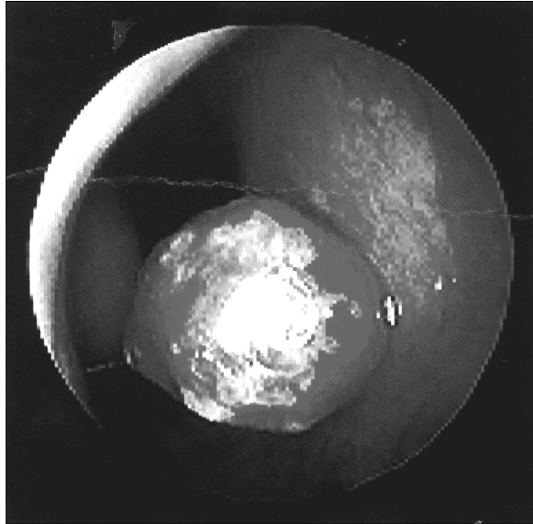


Fig. 1. Endoscopic view of the mass located on the Rt. nasal septum.

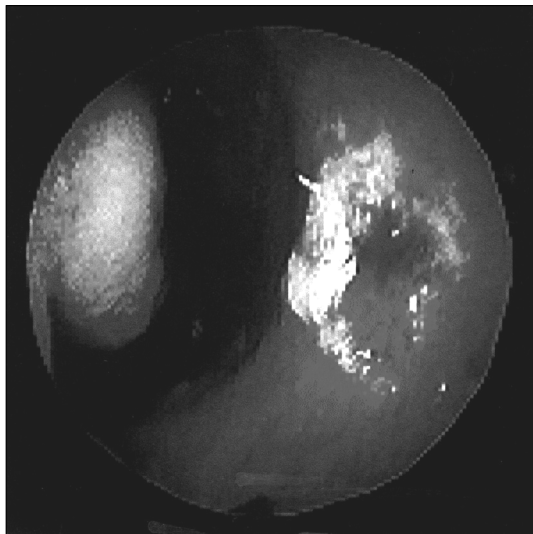


Fig. 2. Postoperative endoscopic view of the Rt. nasal septum.

가 (Fig. 1).
: 1999 2 8

(10% AgNO₃) , .
(Fig. 2).

1 × 1 cm

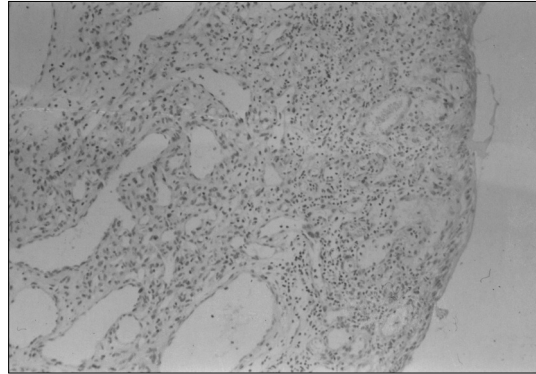


Fig. 3. The lobular capillary hemangioma showing vascular proliferation, edema, inflammation and thinned epidermis (H & E, × 40).

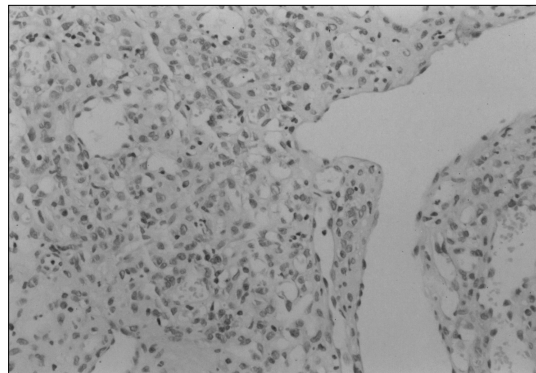


Fig. 4. The lobular capillary hemangioma is composed of typical vascular lobule with a central branching vessel, surrounded by a hypercellular proliferation of endothelial and epithelial cells (H & E, × 100).

고찰

(Figs. 3 and 4).

75.4% 가

18 39 가

1%

2 6)7)

가 가)

5) 4) 7)

5 6 mm 2 3 cm

3) fibromyxoid ma-

trix

3 가

결론

중심 단어 :

REFERENCES

- 1) Setrnberg SS. *Diagnostic surgical pathology: New York Raven press;1989.*
- 2) Leydon JJ, Master GH. *Oral cavity pyogenic granuloma. Arch Derm 1973;108:226-8.*
- 3) K im NY, Choi SM, Kim CH, Oh KK. *Lobular capillary hemangioma (pyogenic granloma). Korean J Otolaryngo 1994;37:1293-7.*
- 4) Fechner RE, Cooper PH, Mills SE. *Pyogenic granuloma of Larynx & Trachea. A causal and pathologic misnomer for granulation tissue. Arch Otolaryngol 1981;107:30-2.*
- 5) Eizinger FM, Weis SW. *Benign tumors & tumorlike lesions of blood vessels. In Soft tissue tumors. St. Louis; The C.V. Mosby Company;1988. p.489-512.*
- 6) Kim BS, Chai GR, Lee YB, Park NM, Park JH. *A case of huge pyogenic granuloma arising from nasal septum. Korean J Otolaryngo 1987;30:155-9.*
- 7) Oh CH, Kim JY, CHO H. *A case of pyogenic granuloma gravidarum. Korean J Otolaryngo 1981;24:728-30.*
- 8) Kapadia SB, Heffner DK. *Pitfalls in the histopathologic diagnosis of pyogenic granuloma. Eur Arch Otorhinolar-yngol 1992;249:195-200.*
- 9) Moon SM, Park NB, Kim YS, Kim CG. *The pyogenic gr-anuloma on the nasal septum. Korean J Otolaryngo 1970; 13:297-9.*
- 10) Bicknell DG. *Granuloma arising in the nasal mucosa du-ring pregnnacy. J Otolaryngo 1974;85:515-20.*