

## 좌측 비강에서 우측 인두주위강에 걸친 금속성 이물의 치험 1례

한장환 · 김상연 · 방진현

### A Case Report of a Metallic Foreign Body Penetrated into Right Parapharyngeal Space from Left Nasal Cavity

Jang-Hwan Han, MD, Sang-Yeon Kim, MD and Jin-Hyeon Bang, MD

*Department of Otolaryngology, Kang Reung Hospital, Kang Reung, Korea*

#### — ABSTRACT —

The foreign bodies in the head and neck areas are common, but metallic foreign bodies are relatively rare. Foreign bodies embedded in soft tissue may remain asymptomatic for a very long time, so a patient may not be aware of these foreign bodies. These foreign bodies can cause toxic and allergic reactions, inflammation, or infection, but the severity of these complications varies widely. Removal can be difficult and time consuming, and the potential damage to surrounded tissues caused by the procedure must be weighed against the risk posed by a particular foreign body. We present a rare case of metallic foreign body in parapharyngeal space for twenty years and make recommendations regarding the successful evaluation and management of a such injuries. (**J Clinical Otolaryngol 1999;10:264-267**)

**KEY WORDS** : Metallic foreign bodies · Endoscopic removal.

서 론

증 례

42

: 1999 4 6

: 1999 11 22

: , 210 - 711

X -

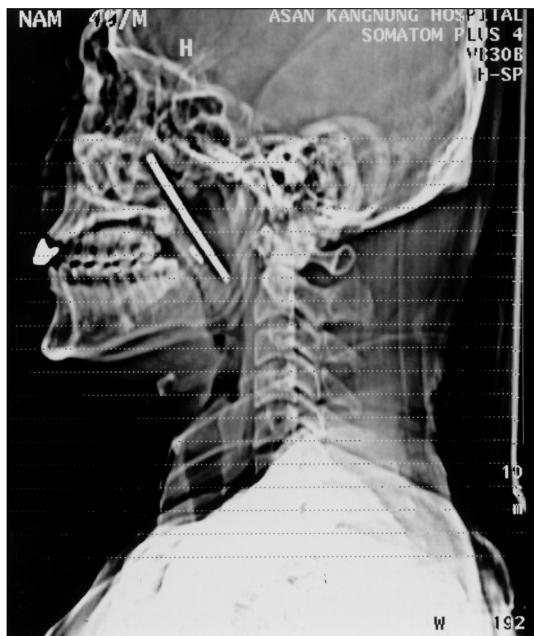
415

: (0391) 610 - 3179 · : (0391) 641 - 8148

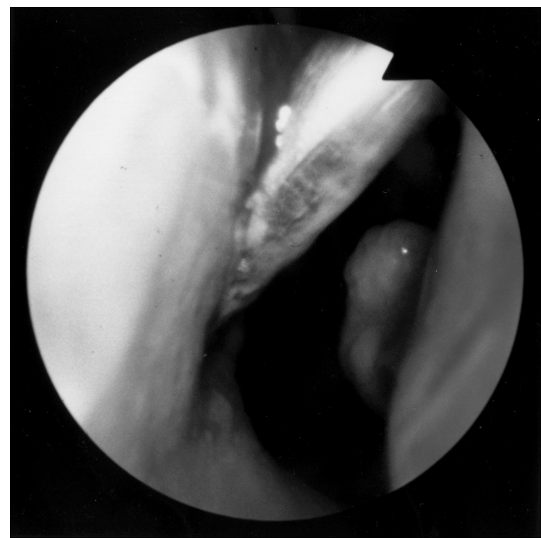
E - mail : jhbang@knh.co.kr

1998 7 16

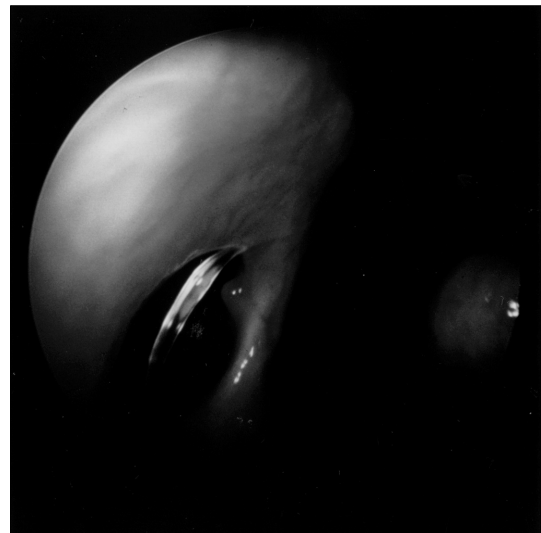
20



**Fig. 1.** Preoperative CT scan demonstrating the foreign bodies penetrated into the parapharyngeal space from the left nasal cavity.



**Fig. 2.** Preoperative endoscopic view of left nasal cavity.



**Fig. 3.** Postoperative endoscopic view of left nasal cavity.

(pharyngomaxillary space), (pt-erygomaxillary space), (pterygopharyngeal space), peripharyngeal space

가  
가 .<sup>6-8)</sup> Bard<sup>9)</sup>

Kjer<sup>10)</sup>

<sup>1)2)</sup>

(prest-yloid space) (retrostyloid space)

<sup>12)</sup>

, 9, 10, 12

20

<sup>1)3)</sup>

, 1979 Gant<sup>4)</sup>

가

1 (supraorbital area) (hair line), (supraorbital ridge)

<sup>8)</sup> Jackson<sup>11)</sup>

, 2

(upper lip)

3 (lower lip)

Gant

Gus-

가

sack<sup>5)</sup>

1

가

가

가

가 . Park<sup>7)</sup> 가

가

2

가

가 . 3

중심 단어 :

REFERENCES

- 1) Dankle SK. *Neoplasm of the parapharyngeal space. Ear Nose and Throat Journal* 1987;66:491-501.
- 2) Heeneman H, Gilbert JJ, Rood SR. *The parapharyngeal*

가

- space: Anatomy and pathologic condition with emphasis on neurogenous tumors. Am Acad Otolaryngol 1980.*
- 3) Kim JB, Kil DS, Suh JH, Kwon HO, Kim CH. *Fibrous histiocytoma in parapharyngeal space. Korean J Otolaryngol 1984;27:608-11.*
  - 4) Gant TD, Epstein LI. *Low-Velocity Gunshot Wound to the Maxillo-facial Complex. J Trauma 1979;19:674-7.*
  - 5) Gussack GS, Jurkovich GJ. *Pediatric penetrating head and neck trauma. Laryngoscope 1990;100:1288-91.*
  - 6) Kim JG, Son IK, Lee CH. *A case of metallic foreign body in the right pterygopalatine fossa-removed through trans-antral approach. Korean J Otolaryngol 1982;25:218-20.*
  - 7) Park CM, Jun WS, Hong ST, Lim JS. *A case of penetrating injury into the ethmoid and skull base by a linear metallic foreign body. Korean J Otolaryngol 1992;35:737-40.*
  - 8) Jin KW, Cho SH. *A case of foreign body in the maxillary sinus. Korean J Otolaryngol 1982;25:202-4.*
  - 9) Bard LA, Jarrett WH. *Intracranial complications of penetrating orbital injuries. Arch Ophthalmol 1964;71:332-4.*
  - 10) Kjer P. *Orbital and transorbital stab wounds. Arch Ophthalmol 1954;51:811-21.*
  - 11) Jackson C, Jackson CL. *Disease of the nose, throat and ear, 2nd ed Philadelphia and London; W.B. Saunders Co; 1959. p.843.*
  - 12) Ben-David J, Fradis M, Podoshin L. *Plasmacytoma arising in the vicinity of a foreign body in the nasal cavity. Laryngoscope 1981;91:1150-92.*