

## Vocal Fold Palsy and Tongue Deviation ; A Case Report of Unpredictable Complications after Endoscopic Sinus Surgery

Ji-Hwan Park, MD, Dong-Won Kim, MD, Jae-Wook Kim, MD and Sung-Lyong Hong, MD

*Department of Otorhinolaryngology-Head and Neck Surgery, Pusan National University Hospital,  
Busan, Korea*

### — ABSTRACT —

Endoscopic sinus surgery has been widely used as a relatively safe and effective treatment for paranasal sinus disorders. There are some complications which can be anticipated but sometimes they can be unexpected. Herein, we report a case of vocal fold palsy along with tongue deviation as complications of endoscopic sinus surgery which was resolved completely over a few months without leaving any neurologic deficit. (*J Clinical Otolaryngol* 2016;27:354-356)

**KEY WORDS** : Case report · Tapia syndrome · Endoscopic sinus surgery · Vocal fold palsy.

### Introduction

Endoscopic sinus surgery (ESS) has been widely used as a relatively safe and effective treatment for paranasal sinus disorders. There are some complications after ESS which can be anticipated such as post-operative hemorrhage, Cerebrospinal fluid (CSF) leakage, and orbital complications. However, an unexpected complication which does not seem to be related with sinonasal anatomy can occur.

Herein, we report a case of a 32 year-old man who was found to have unilateral vocal fold palsy along with ipsilateral hypoglossal nerve palsy after bilateral ESS which was resolved completely over a few months without leaving any neurologic deficit.

### Case Report

A 32-year-old male without any previous medical history visited to the ENT outpatient department (OPD) with the chief complaint of hyposmia with bilateral nasal obstruction, rhinorrhea and postnasal drip for a few months. There were no specific findings in naso-endoscopic examination. Although the patient was recommended to get further medical treatment, as he felt the medication was unhelpful, he insisted to have a surgery for his problems. With the impression of chronic rhinosinusitis, paranasal computed tomography scan was taken. He was found to have bilateral ethmoidal, sphenoidal and frontal sinusitis, and then he was scheduled for a bilateral ESS under general anesthesia.

Routine preoperative evaluation including blood tests, urinalysis, chest X-ray, electrocardiogram, pulmonary function test showed no significant abnormal findings. The operation was done without any difficulty in a routine manner. The trans-oral intubation was performed smoothly by direct laryngoscopy. There was no problem during the intubation.

After adjustment of the depth of the endotracheal tube, the cuff was inflated, and the tube was placed in

논문접수일 : 2016년 8월 1일

논문수정일 : 2016년 9월 8일

심사완료일 : 2016년 10월 27일

교신저자 : 홍성룡, 49241 부산광역시 서구 구덕로 179

부산대학교 의학전문대학원 이비인후과학교실

전화 : (051) 240-7396 · 전송 : (051) 246-8668

E-mail : st-dragonhong@hanmail.net

the right lateral angle of the lower lip. During the operation, the patient was kept in semi-recumbent position, and the patient's head was not repositioned. The routine procedures of ESS were performed successfully, and at the end of the procedure, nasal cavities were packed with non-degradable material which was intended to be removed 2 days after the operation. The overall procedure was uneventful.

Two days after the surgery, during the removal of nasal packing, the patient complained of hoarseness and difficulty in tongue movement which were getting worse day by day. When he protruded his tongue, it was slightly deviated to the left side. The fiberoptic laryngoscopic examination showed a paramedian fixation of the left vocal fold (Fig. 1). Any other neurologic abnormalities were not found. The patient was referred to a neurologist and underwent magnetic resonance imaging with angiography for ruling out central neurologic deficit, but the result was unremarkable.

With the diagnosis of left vocal fold palsy and hypoglossal nerve palsy, 5mg of dexamethasone was injected intravenously 4 times a day, and then the dose was tapered down over 14 days. He was discharged 20 days after the operation. One month after the surgery, tongue movement and hoarseness seemed to be slightly improved. Three months after the surgery,

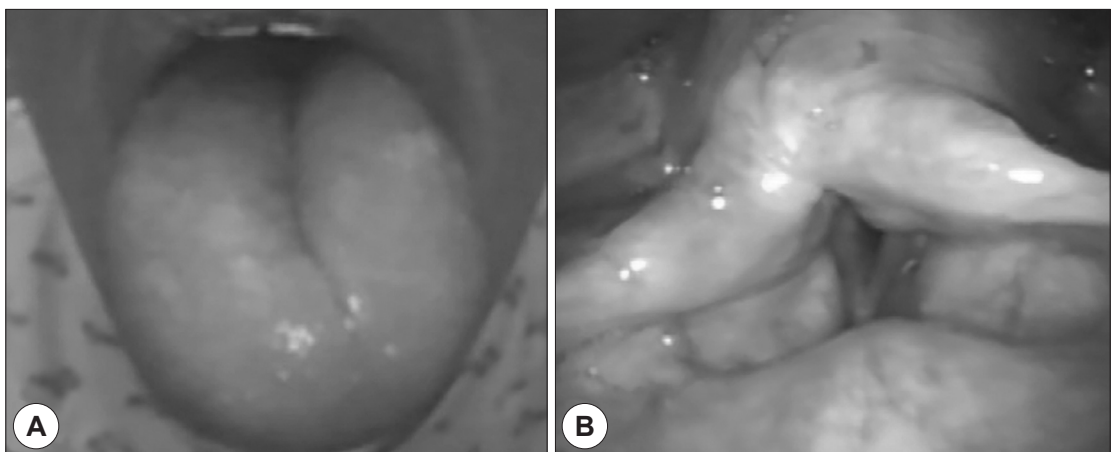
they became almost normal, but he still complained of difficulty in making a loud voice. Six months after the surgery, all of the symptoms became normal.

## Discussion

ESS is an effective treatment modality and a relatively safe procedure.<sup>1)</sup> A retrospective analysis reported the overall major complication rate following primary ESS is low with a rate of 0.36%.<sup>1)</sup> However, there is always risk for complications, and sometimes there are some complications that cannot be anticipated such as vocal fold palsy with tongue deviation.

In 1906, Spanish otorhinolaryngologist Antonio Garcia Tapia first described a lesion of the vagus and hypoglossal nerves with contralateral hemiplegia. The most common clinical symptoms are hoarseness, dysphagia and difficulty in tongue movement.<sup>2)</sup> However, most of the later reports described Tapia syndrome as a peripheral disease.<sup>3)</sup> It results from an injury to the cranial nerve X and XII without involvement of the pharyngeal branches of the cranial nerve X and affects the ipsilateral vocal cord and tongue.<sup>4)</sup> To the best of our knowledge, a very limited number of cases have been reported.

Tapia syndrome is believed to be caused by a neu-



**Fig. 1.** Neurologic abnormalities of the patient after endoscopic sinus surgery. A : When the patient protruded his tongue, it was deviated to the left side. B : Fiberoptic laryngoscopic examination showed paramedian fixation of the left vocal fold palsy.

ropraxic reaction of both nerves due erroneous positioning of the mask, excessive cuff pressure and position of the patient during general anesthesia.<sup>5)</sup> Lowinger et al. reported a neuropraxic injury of not only the recurrent laryngeal nerve but also adjacent nerves, namely the hypoglossal and lingual nerve following the use of laryngeal mask airway.<sup>6)</sup> However, the precise etiology of nerve damage associated with the laryngeal mask has not been determined.<sup>5)</sup> The hypoglossal nerve is vulnerable as it runs above and deep to the hyoid bone, the lingual nerve may be compressed between the mandible and a tube lying lateral to the tongue, and the recurrent laryngeal nerve, on one or both sides, may be compressed between the cuff and cricoid or thyroid cartilage.<sup>6)</sup> In addition, Paramalingam et al. suggested Eagle syndrome as a potential cause of Tapia syndrome.<sup>7)</sup> Since vagus nerve and hypoglossal nerve is in close relationship anatomically around jugular foramen region, these nerves can be injured simultaneously.<sup>8)</sup>

Tapia syndrome which occurred after ESS has never been reported. However, one study reported that it occurred after rhinoplasty.<sup>5)</sup> Even though it does not seem to be related with sinonasal anatomy, its relationship with sinonasal surgery cannot be ruled out. In the present case, two possible mechanisms could be considered. One is by cuff pressure of the endotracheal tube, and the other is stretching of nerves by flexion or extension of the head during positioning the patient, even though there was no remarkable event during both anesthesia and surgery.

Because Tapia syndrome is a neuropraxic injury of nerves, it usually recovers naturally over time. Most cases in literatures heal within 4 to 6 months with supportive care.<sup>9)</sup> Boga et al. recommended corticosteroid as the key drug.<sup>4)</sup> In the acute setting, intravenous or oral steroids for 10 to 14 days have been used most frequently.<sup>10)</sup> As systemic corticosteroid itself could cause complications, close follow-up is necessary. Some have also advocated for the use of vitamins (B1, B6, B12, or their combinations) for up to 3 months.<sup>10)</sup> Only follow-ups without corticosteroid for mild cases are

recommended.<sup>4)</sup>

Although ESS has been widely used as a relatively safe and effective treatment for paranasal sinus disorders, it is possible that we could confront some unexpected postoperative complications. In fact, Tapia syndrome, a rare state which is characterized by unilateral paralysis of tongue and ipsilateral vocal fold due to a temporary injury of cranial nerve X and XII, could occur after any surgery under general anesthesia. We should be aware of the possible mechanism of this rare injury, and pay more attention during airway management and positioning the head of the patient.

---

This work was supported by clinical research grant from Pusan National University Hospital 2016.

## REFERENCES

- 1) Krings JG, Kallogjeri D, Wineland A, Nepple KG, Piccirillo JF, Getz AE. *Complications of primary and revision functional endoscopic sinus surgery for chronic rhinosinusitis. Laryngoscope* 2014;124(4):838-45.
- 2) Andrioli G, Rigobello L, Mingrino S, Toso V. *Tapia's syndrome caused by a neurofibroma of the hypoglossal and vagus nerves: case report. J Neurosurg* 1980;52(5):730-2.
- 3) Al-Sihan M Jr, Schumacher M, Lohle E. *Tapia syndrome caused by a vertebral artery dissection. Ear Nose Throat J* 2011;90(7):313-4.
- 4) Boga I, Aktas S. *Treatment, classification, and review of Tapia syndrome. J Craniofac Surg* 2010;21(1):278-80.
- 5) Tesei F, Poveda LM, Strali W, Tosi L, Magnani G, Farneti G. *Unilateral laryngeal and hypoglossal paralysis (Tapia's syndrome) following rhinoplasty in general anaesthesia: case report and review of the literature. Acta Otorhinolaryngol Ital* 2006;26(4):219-21.
- 6) Lowinger D, Benjamin B, Gadd L. *Recurrent laryngeal nerve injury caused by a laryngeal mask airway. Anaesth Intensive Care* 1999;27(2):202-5.
- 7) Paramalingam S, Kuok YJ. *Eagle Syndrome as a potential cause of Tapia Syndrome. Med J Aust* 2015;202(9):491.
- 8) Kang JH, Kim DM, Kim SW. *Tapia syndrome after cervical spine surgery. Korean J Spine* 2013;10(4):249-51.
- 9) Park CK, Lee DC, Park CJ, Hwang JH. *Tapia's Syndrome after Posterior Cervical Spine Surgery under General Anesthesia. J Korean Neurosurg Soc* 2013;54(5):423-5.
- 10) Gevorgyan A, Nedzelski JM. *A late recognition of tapia syndrome: a case report and literature review. Laryngoscope* 2013;123(10):2423-7.
- 11) Kim JS, Do HW. *Basic surgical technique for endoscopic sinus surgery. J Clinical Otolaryngol* 2002;13(2):155-9.