

## 신이식 후 연구개와 구개 편도에 발생한 Epstein-Barr Virus 양성인 말초성 T 세포 림프종 1예

인제대학교 의과대학 부산백병원 이비인후-두경부외과학교실,<sup>1</sup> 병리학교실<sup>2</sup>

김상렬<sup>1</sup> · 엄재욱<sup>1</sup> · 최정배<sup>1</sup> · 김찬환<sup>2</sup>

### A Case of Epstein-Barr Virus-associated Peripheral T-cell Lymphoma Involving Soft Palate and Left Palatine Tonsil in Renal Transplant Recipient

Sang Ryul Kim, MD<sup>1</sup>, Jae Wook Eom, MD<sup>1</sup>, Jung Bae Choi, MD<sup>1</sup> and Chan Hwan Kim, MD<sup>2</sup>

<sup>1</sup>Department of Otolaryngology-Head & Neck Surgery and <sup>2</sup>Pathology, College of Medicine, Inje University,  
Pusan Paik Hospital, Busan, Korea

#### —ABSTRACT—

Posttransplant lymphoproliferative disorder (PTLD) is a heterogenous group of lymphoid proliferative disorders ranging from non-specific reactive hyperplasia to malignant lymphoma occurring in transplant patients. The origins of PTLD are mostly B lymphocytes and linked to Epstein-Barr virus (EBV) infection, but T lymphocyte PTLDs are uncommon and not associated with EBV infection. We report a case of EBV-associated peripheral T-cell lymphoma involving soft palate and left palatine tonsil occurring in a 35 year old female patient 14 years after renal allograft transplantation. Positivity for CD3 demonstrated in the tumor cells, while CD56 was not expressed. We detected positive reaction for EBV-encoded RNAs (EBERs) in the neoplastic cells by in situ hybridization. She is being treated by chemotherapy at present after surgical removal of lesion and reduction of immunosuppression. (J Clinical Otolaryngol 2004;15:286-289)

**KEY WORDS** : Posttransplant lymphoproliferative disorder (PTLD) · Peripheral T-cell lymphoma · Epstein-Barr virus · Renal transplantation · Soft palate.

#### 서 론

(posttransplant lympho-  
proliferative disorder, PTLD)

: 2004 10 3

: 2004 11 23

: , 614 - 735

633 - 165

: (051) 890 - 6176 · : (051) 892 - 3831

E - mail : iment1@yahoo.co.kr

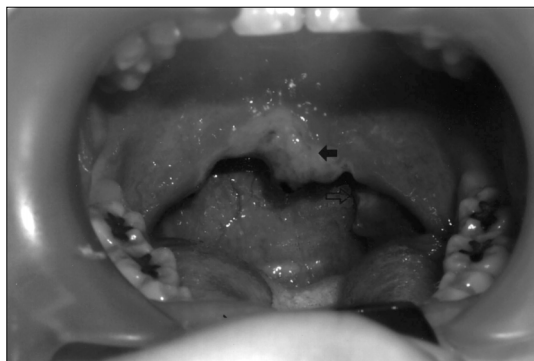
1)  
B 87%, T 13%, null  
0.5%,<sup>2)3)</sup> B Epstein-Barr virus(EBV) 가<sup>2)3)</sup>  
T EBV  
T PTLD T

3-5)  
 EBV T  
 증례  
 35 가 2  
 가 14  
 cyclosporin, azathioprine,  
 prednisolone

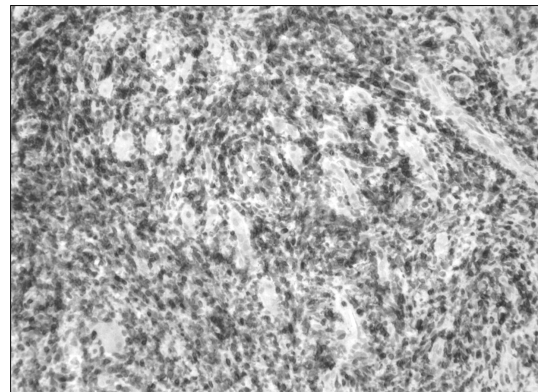
Epstein - Barr Virus T 1  
 (Fig. 1).

가  
 (Fig. 2)  
 T CD3, CD45RO  
 (Fig. 3.) B CD56  
 (Fig. 4).  
 (in situ hybridization) EBV - en-  
 coded RNAs(EBERs) (Fig. 5).

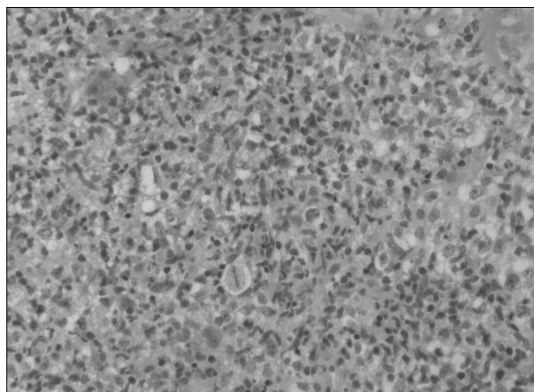
Lactate dehydrogenase(LDH), 2 - micro-



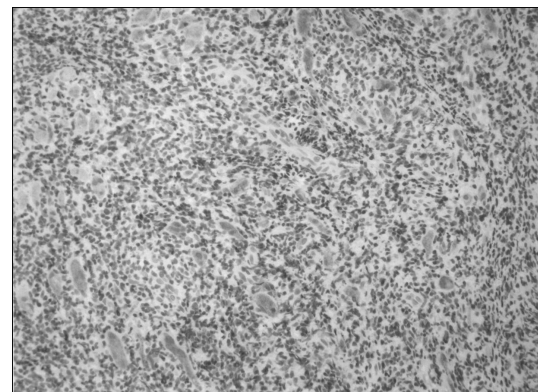
**Fig. 1.** Ulcerative lesion involving soft palate (black arrow) and left palatine tonsil (white arrow).



**Fig. 3.** The neoplastic lymphoid cells are positive for immunohistochemical staining of CD3.



**Fig. 2.** The infiltrating lymphoid cells are variable-sized and cytologically atypical (H & E,  $\times 200$ ).



**Fig. 4.** The neoplastic lymphoid cells are negative for immunohistochemical staining of CD56.

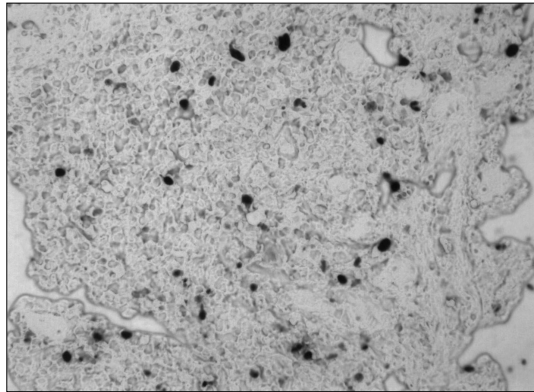


Fig. 5. Some number of neoplastic lymphoid cells show positive reaction for EBV in situ hybridization.

globulin, LDH Human T cell lymphotropic virus type I/II (HTLV - I/II), EBV viral capsid antigen (VCA) IgM, EBV viral capsid antigen (VCA) Ig G 1 : 200, EBV nuclear antigen (EBNA) 1 : 80

CHOP (Cyclophosphamide, Doxorubicin, Vincristine, Prednisolone)

### 고찰

(PTLD)<sup>1)</sup>

B EBV<sup>1)6)</sup> EBV B Na-tural killer (NK), T 가 EBV 가 EBV B EBV PTLD가 Sha- piro<sup>7)</sup> EBV가

PTLD가  
PTLD  
EBV - DNA<sup>7)</sup>  
EBV 가<sup>2)3)8)</sup>  
PTLD  
cyclosporin A  
tacrolimus (FK506)  
cyclosporin A 가  
PTLD 가<sup>11)</sup> Merlino<sup>12)</sup>  
cyclosporin A tacrolimus (FK506)  
EBV - DNA 가  
B T<sup>9)10)</sup>  
cyclosporin, azathioprine,  
prednisolone 가 1  
cyclosporin tacrolimus (FK506)  
EBV T<sup>3-5)</sup> Meijer<sup>13)</sup>  
가  
가  
B PTLD  
가  
antiviral agent EBV<sup>13)14)</sup> Hanto<sup>6)</sup>  
T PTLD  
가

가 14

T

중심 단어 :

· Epstein - Barr virus ·

T

## REFERENCES

- 1) Frizzera G. *Atypical lymphoproliferative disorders*. In: Knowles DM, editor. *Neoplastic hematopathology*. Baltimore: Williams and Wilkins; 2001. p.596-622.
- 2) Penn I. *The problem of cancer in organ transplant recipients: an overview*. *Transplant Sci* 1994;4:23-37.
- 3) Dockrell DH, Strickler JG, Paya CV. *Epstein-Barr virus induced T cell lymphoma in solid organ transplant recipients*. *Clin Infect Dis* 1998;26:180-2.
- 4) Leblond V, Davi F, Charlotte F. *Post-transplant lymphoproliferative disorders not associated with Epstein-Barr virus: a distinct entity?* *J Clin Oncol* 1998;16:2052-9.
- 5) Feher O, Babrilla D, Locker J, Oliveri D, Melhem M, Winkelstein A. *T-cell large granular lymphocytic leukemia following orthotopic transplantation*. *Am J Hemato* 1995;49:216-20.
- 6) Hanto DW, Gaji-Peczalska KJ, Frizzera G, Arthur DC, Balfour HH, McClain K, et al. *Epstein-Barr virus (EBV) induced polyclonal and monoclonal B-cell lymphoproliferative disease occurring after renal transplantation*. *Ann Surg* 1983;198:356-69.
- 7) Shapiro R, Nalesnik M, McCauley J, Fedorek S, Jordan ML, Scantlebury VP, et al. *Posttransplant lymphoproliferative disorders in adult and pediatric renal transplant patients receiving tacrolimus-based immunosuppression*. *Transplantation* 1999;68 (12):1851-4.
- 8) Lye WC. *Successful treatment of Epstein-Barr virus (EBV) associated T cell cutaneous lymphoma in a renal allograft recipient: case report and review of the literature*. *Transplant Proc* 2000;32:1988-9.
- 9) Penn I. *Cancers complicating organ transplantation*. *N Engl J Med* 1990;323:1767-9.
- 10) Penn I. *The changing pattern of posttransplant malignancies*. *Transplant Proc* 1991;23:1101-3.
- 11) Cacciarelli TV, Reyes J, Jaffe R, Mazariegos GV, Jain A, Fung JJ, et al. *Primary tacrolimus (FK506) therapy and the long-term risk of post-transplant lymphoproliferative disease in pediatric liver transplant recipients*. *Pediatr Transplantation* 2001;5:359-64.
- 12) Merlino C, Cavallo R, Bergallo M, Giacchino F, Bollero C, Negro Ponzi A, et al. *Epstein Barr virus load monitoring by quantitative PCR in renal transplant patients*. *New Microbiol* 2003;26 (2):141-9.
- 13) Meijer CJ, Jiwa NM, Dukers DF, Oudenjans JJ, Bruin PC, Walboomers JM, et al. *Epstein-Barr virus and human T-cell lymphoma*. *Semin Cancer Biol* 1996;7:191-6.
- 14) Nalesnik MA. *Clinical and pathologic features of post-transplant lymphoproliferative disorder (PTLD)*. *Semin Immunopathol* 1998;20:325-42.