

## 인공와우이식을 위한 기존 절개법과 최소 절개법의 비교

순천향대학교 의과대학 이비인후과학교실

김 시 찬

## Comparison between the Conventional and Minimal Incision for the Cochlear Implantation

Shi-Chan Kim, MD

Department of Otorhinolaryngology, Soonchunhyang University, College of Medicine, Bucheon, Korea

## -ABSTRACT-

**Background and Objectives** : The surgical complications of the cochlear implantation are rare but most of them are flap-related. The author simplified the previous minimal incision with operating microscope only. The minimal incision method was compared retrospectively with the conventional incision method. **Materials and Methods** : The approach with "V" shaped incision less than 4 cm was done to nine patients. Eight patients were done with the conventional "S" shaped incision. These results of the both methods were analyzed. **Results** : There is no major complication in both groups. One case of the conventional method group showed the hematoma. One case with the minimal incision method showed the erythema. **Conclusions** : The minimal incision surgery for the cochlear implant is possible to perform without major complications and large scars. (J Clinical Otolaryngol 2004;15:88-92)

**KEY WORDS** : Cochlear implantation · Surgical procedure, minimally invasive.

## 서 론

S

가

가

가

1)

: 2004 3 30

: 2004 5 21

: , 420 - 600

1174

: (032) 621 - 5017 · : (032) 621 - 5018

E - mail : drsckim@schbc.ac.kr

2)

가

3)

대상 및 방법

대상  
2002 1 2003 4

17  
V  
9 6  
3 4.9 ( : 20 ~ 25 ).  
Nucleus 24 contour(Cochlear, Australia)  
S  
8 2 6  
10.7 ( : 2~35 ).  
Nucleus 24 contour(Cochlear, Australia),  
Combi 40+(Medel, Austria)가  
12

방법

O'Donoghue 3)  
(postauricular crease) 0.5 cm  
V  
4 cm (Fig. 1).  
(linea temporalis)

Raney clip  
(retractor)  
Senn  
가 가 "S"

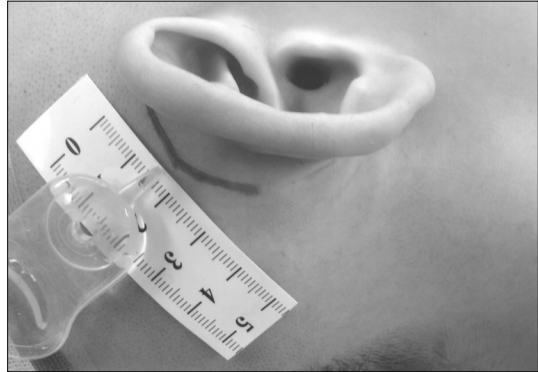


Fig. 1. The design of the incision through the line between the postauricular crease and implant dummy.

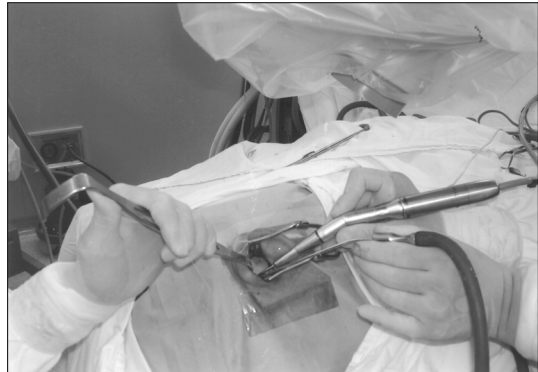

Fig. 2. The patient is rotated toward the surgeon to obtain the appropriate surgical view.

Ar-  
my - Navy  
가 (Fig. 2).  
가 1 cm  
가  
(Fig. 3).

7  
가 가 (Fig. 4).  
"S"



:

Gibson 6 10.3% Harrison<sup>6)</sup> C<sup>5)</sup> O Donoghue 가  
 , C 가  
 , 가  
 , 가  
 Kempf Lenarz<sup>7)</sup> 가  
 , Army - Navy 가  
 , 가  
 , 1.5 cm 가  
 O 'Donoghue<sup>3)</sup> 가 가 가  
 3~4 cm 가 가 가  
 , 가  
 , 가  
 , Nucleus 24 가 가  
 가 가  
 가 가  
 , 가  
 O 'Donoghue 가 가  
 ,  
 O 'Donoghue 가  
 ,  
 가  
 V 가 (dead space)

1 6

가

O Donoghue

### 결 론

가

가

가

cleus 24 contour

1

Nu-  
12

중심 단어 :

### REFERENCES

- 1) Johnson IJ, Gibbin KP, O'Donoghue GM. *Surgical aspects of cochlear implantation in young children: A review of 115 cases. Am J Otol 1997;18:S69-70.*
- 2) Hoffman RA, Cohen NL. *Complications of cochlear implant surgery. Ann Otol Rhinol Laryngol 1995;166:420-2.*
- 3) O'Donoghue GM, Nikolopoulos TP. *Minimal access surgery for pediatric cochlear implantation. Otology & Neurotology 2002;23:891-4.*
- 4) Cohen NL, Hoffman RA, Stroschein M. *Medical or surgical complications related to the Nucleus multichannel cochlear implant. Ann Otol Rhinol Laryngol 1988;97:8-13.*
- 5) Telian SA, El-Kashlan HK, Arts HA. *Minimizing wound complications in cochlear implant surgery. Am J Otol 1999; 20:331-4.*
- 6) Gibson WP, Harrison HC. *Further exposure with a straight, vertical incision for placement of cochlear implants. J Laryngol Otol 1997;111:924-7.*
- 7) Kempf HG, Lenarz KJ. *Complications in pediatric cochlear implant surgery. Eur Arch Otorhinolaryngol 1999; 256:128-32.*

, 1  
가  
가

가

12